



Uranium and Lead Intoxication Hazards Induce Hepatotoxicity In Rats; Biochemical, Histochemical And Histopathological Studies

Hazem K A. Sarhan

Medical and radiation research Dep. Research Sector, Nuclear Material Authority, Cairo, Egypt



CrossMark

Abstract

Depleted uranium (DU) used in each of civilian and military activities and contributes to health problems. Uranium is an element of heavy metals with chemical and radiological nature that have made it useful in industry and commerce, but toxic at sufficiently high doses to both humans and the environment. Also, Lead is one of the naturally occurring environmental heavy metals. This experimental study was designed to evaluate uranium and lead-induced hepatotoxicity. Material and Methods: This study was conducted in the Medical and Radiation Research Department, Research Sector, Nuclear Material Authority, Cairo, Egypt. from September to December 2020 on 30 normal healthy adult male albino rats divided into three equal groups each of 10 rats. Control group rats were kept on a normal diet and pure distilled water (Group A). The 2 experimental groups were kept on a normal diet and rats were administered with 50 mg/kg body weight of lead acetate only for 45 days, (Group B) and rats were administered with 40 mg/kg body weight of uranyl acetate only for 45 days (Group C). Animals were sacrificed and livers were removed and used to identify microscopic changes. Specimens were stained with Hematoxylin and eosin, with Masson trichrome stain for the study of fibrous tissue. Results: Mild lymphocytic infiltration, vacuolar degeneration, and mild increase of periportal fibrosis with mild depletion of glycogen significance and partial disappearance of glycogen vacuoles were reported in animals that received lead acetate contaminated water for 6 weeks. Animals that received uranyl acetate contaminated water for 6 weeks showed hepatic changes in the form of abundant lymphocytic infiltration, increased cellular polymorphism, pyknotic nuclei, and areas of cell necrosis with evident moderate periportal fibrosis and marked vacuolar degeneration associated with marked depletion of glycogen level. Conclusion: It could be concluded that exposure to uranium as compared to lead imposes a potent toxic effect on liver cells listing as glycogen depletion, cellular infiltration, and liver architecture in the form of initiation of periportal fibrosis that may progress to liver cirrhosis.

keywords: Heavy metal, Uranium acetate, Lead acetate, Hepatotoxicity, Antioxidants, histopathology, and Rats

1. Introduction

Depleted uranium (DU) is uranium that contains less of the fissile isotope ^{235}U than natural uranium. The isotopic composition of DU is typically 99.977% ^{238}U , 0.2% ^{235}U , and 0.0008976% ^{234}U . DU is what residue after the removal of enriched uranium, and may also be generated from the reprocessing of spent nuclear reactor fuel [1]. DU is known to make both radioactive and chemical toxicity [2]. The radioactivity of DU is near to 60% that of natural uranium, and their chemical properties are similar. Due to its economic price, high penetrability, and pyrophoricity, DU used in each of military and civilian activities [3]. At high temperatures, it can destroy armored and fortified structures and vehicles.

DU may be released into the environment as it is mined, processed, and applied. East Germany and Czechoslovakia released one billion tons of uraniummined ores and residues into soil and surface waters between 1945 and

1989 [4]. NATO forces used DU weapons against Serbian heavy infantry in the Kosovo conflict in 1999, and more than 9 tons of DU was used in the war, raising concerns worldwide [5]. DU weapons have also been in other wars, including the Persian Gulf War and the Balkans conflicts. The physical half-life of DU exceeds 4.49×10^9 years, and it can remain in soil and groundwater a long time, affecting local ecosystems [3].

DU enters the body via inhalation, ingestion, or dermal contact, damaging tissue. Both acute and chronic exposure can cause adverse reactions, but chemical toxicity mainly comes from acute exposure. The kidney, liver, spleen, and bone marrow are the most vulnerable targets. Kidney and liver DU toxicity is characterized by proximal renal tubular damage and hepatotoxicity, which may lead to necrosis of renal tubules and liver cells [6]. Administration of intragastric DU (204 mg/kg) in rats will alter the

*Corresponding author e-mail: Hazem_Kamel1980@yahoo.com; (Hazem K. A. Sarhan).

Receive Date: 28 June 2021, Revise Date: 17 July 2021, Accept Date: 26 July 2021

DOI: 10.21608/EJCHEM.2021.82995.4079

©2021 National Information and Documentation Center (NIDOC)

expression of cytochrome enzymes involved in vitamin D metabolism in the liver and kidneys [7].

In mining and grinding facilities, uranium is a dust particle with an average diameter of 5 microns. Compared with larger particles, the larger the surface areas per unit volume, the more biologically active nanoparticles are [8]. The small size of uranium particles facilitates their absorption by human cells, thus passing through epithelial cells and endothelial cells into the blood and lymphatic circulation, thereby reaching potential sensitive targets. Several studies have focused on uranium-induced toxicity, emphasizing its role in the production of reactive oxygen species (free radicals), especially reactive oxygen species (ROS) into biological systems [9]. Many studies showed that uranium intoxication induce hazardous effects on kidneys [10], liver [11].

Lead is absorbed into the body by breathing polluted air, drinking contaminated water and food. Water from lead pipes may be contaminated with lead. Fumes from automobile exhaust, lead-based paints polluted air from industrial plants, or cigarette smoke may all contain lead. Many lead-containing products, however, are now outlawed [12]. Lead has no beneficial role in body functions, cellular growth, proliferation, or signaling and there is no "safe" level of exposure has been reported [13].

Analogous other naturally occurring heavy metals-arsenic, mercury, and cadmium -lead also changes cellular genetics, damages cellular substances and attack cellular membrane structure. Generally, the lead toxicity mechanism involves oxidative damage-induce reactive oxygen species (ROS) affecting cell membranes, disturbance of hepatocytes antioxidant system, troubles of liver enzymes markers, and activation of transcription-sensitive factors [14, 15].

The liver is divided into tiny clusters of cells, which are functionally located around the terminal venules in the acinar unit. Blood flows from the terminal portal venules into the sinusoids and comes into contact with hepatocytes within the unit until it drains into the terminal hepatic venules. Hepatocytes, representing approximately 60% of the liver cells, are 13 - 30 μ in diameter and have eight or more surfaces. Each hepatocyte has both a microvillar and straight surfaces. The microvilli face the perisinusoidal space and extend into the pericellular space [16].

Cytoplasm of Hepatocyte typically displays much granular and a granular endoplasmic reticulum, lysosomes, many well-developed Golgi bodies, and many mitochondria, countenance indicating a high metabolic activity. Lipid vacuoles and Glycogen granules are usually prominent. Abundant, particularly large

peroxisomes and vacuoles containing enzymes indicate complex metabolism in these cells [17].

Regardless of liver being not a target for lead or uranium toxic insult, **Bleise et al.** and **Wilczynska et al.** [3, 18], who conducted a retrospective observation covered 4.556 males with occupational disease, obvious by lead or uranium toxicity and noted increased total mortality among lead or uranium intoxicated males with significant excess mortality was observed in diseases of the digestive system including chronic hepatitis and cirrhosis [7, 18]. The mechanism of lead or uranium-induced liver toxicity is not very clear [6, 19]. This prospective experimental study was designed to evaluate the lead or uranium induced toxic effects on hepatocytes and lobular architecture as judged microscopically.

2. Material & Methods

This study was conducted in Medical and Radiation Research Department, Research Sector, Nuclear Material Authority, Cairo, Egypt. September to December 2020 on 30 normal healthy adult male albino rats. Rats (150–200 g) were obtained from Egyptian Organization for Biological Products and Vaccines. Rats were kept under standard conditions (temperature 20°C, 60% humidity and 12 hours day/night cycle), and maintained on standard diet and pure distilled water till start of study regimens. The animals were divided into three equal groups each of 10 rats. Control group rats were kept on normal diet and pure distilled water (**Group A**). The 2 experimental groups were kept on normal diet and rats were administered with 50 mg/kg body weight of lead acetate only for 45 days (every other day) (**Group B**) [20] and rats were administered with 40 mg/kg body weight of uranyl acetate only for 45 days (every other day) (**Group C**) [21]. Rats were grown each group in a separate cage under standard conditions throughout the study period.

2.1. Experimental Design

The rats were randomly assigned into 3 groups of 10 rats each (Groups A, B, and C). Animals were treated as follows;

Group A: (Normal Control): Control, rats were given normal feed and distilled water only.

Group B: the rats in this group were orally administered with lead acetate 50 mg/kg b. wt. for 45 days (every other day).

Group C: the rats in this group were orally administered with uranyl acetate dihydrate 40 mg/kg b. wt. for 45 days (every other day).

Lead acetate and Uranyl acetate were dissolved in distilled water before use. Lead and uranium are given by oral gavage. Twenty-four hours after the last administration, the animals were sacrificed by cervical dislocation. Through a midline incision on the anterior abdominal

wall, the heart was accessed and blood samples were collected by cardiac puncture. These were stored in 5 ml plain bottle for biochemical evaluation. The liver was quickly excised, and its absolute weight obtained using a top loader sensitive balance (Mettler Toledo Germany), and immediately fixed in 10% phosphate buffered formalin for 24 hours for subsequent histological and immunohistochemical analysis. For histological & histopathological examinations small pieces of the liver were fixed in 10% neutral formalin & prepared for Hematoxylin & Eosin stain, and trichrome stain [22] which stains the fibrous tissue. For histochemical study, other specimens were fixed in alcoholic bouin's fluid for glycogen demonstration using [23] periodic acid Schiff's (PAS) technique. Uranyl acetate dehydrated ($\text{UO}_2\text{CH}_3\text{OCO}_2 \cdot 2\text{H}_2\text{O}$) was purchased from Electronic Microscope Sciences (Ft. Washington, PA). Lead acetate obtained from Carlo-Erba Chemicals, France, and all other chemicals were of analytical grade.

2.2. Preparation of liver homogenate

Liver samples were removed, cleared off blood and immediately transferred to ice-cold containers containing 0.9% saline. A known amount of tissue was homogenized using appropriate phosphate buffer (according to the assay procedures) in a tissue homogenizer (Glas-Col®, Cat no.099C K6424, TERRE HAUTE USA). For performing biochemical assays, a 10% liver homogenate in 10 mM phosphate buffer was prepared, centrifuged at $10,000 \times g$ for 15 min at 4 °C and the supernatant was collected and stored at -80 °C to perform total thiobarbituric acid reactive substances (TBARS) determination, GSH content and CAT activity tests.

2.3. Antioxidant evaluation

To evaluate lipid peroxidation, the method described by **Ohkawa et al.** [24], was used to measure the hepatic tissue content of malondialdehyde (MDA), using Assay Kits (BIODIAGNOSTIC, Egypt). Briefly, 0.2 ml of liver homogenate or standard was mixed with 1 ml chromogen solution (Thiobarbituric acid + detergent + stabilizer) and heated in a boiling water bath for 30 min.

TBARS were determined by measuring the absorbance at 534 nm and expressed as MDA (nmol/g tissue).

According to the provider's instructions, **Ellman** [25], the tissue level of GSH was determined by a test kit (BIODIAGNOSTIC, Egypt). Levels of GSH in liver homogenates were assayed by mixing 0.5 ml of homogenate with 0.5 ml TCA and centrifugation at 3000 rpm for 15 min. Then, 0.5 ml of supernatant was mixed with 1 ml of phosphate buffer (pH 8) and 0.1 ml of 5, 5'-dithiobis-2-nitrobenzoic acid (DTNB). The yellow-colored substance formed was measured at 405 nm. The results were expressed as GSH mg/g tissue.

Determination of catalase (CAT) activity was carried out according to the colorimetric assay described by **Aebi**, [26]. Catalase decomposes hydrogen peroxide (H_2O_2) by

two different reaction pathways. This assay method is based on the measurement of the hydrogen peroxide substrate remaining after the action of catalase. First, the catalase converts hydrogen peroxide to water and oxygen and then this enzymatic reaction is stopped with sodium azide. An aliquot of the reaction mix is then assayed for the amount of hydrogen peroxide remaining by a colorimetric method. Unit definition: One unit of catalase will decompose 1.0 micromole of hydrogen peroxide to oxygen and water per minute at pH 7.0 at 25 °C at a substrate concentration of 50 mM hydrogen peroxide ($\mu\text{mol H}_2\text{O}_2/\text{min/g}$).

2.4. Assessment of serum liver injury markers

Liver enzymes (AST, ALT and ALP activities) were determined in the serum using Assay Kits (BioMed, Egypt) according to the provider instructions. Briefly, 0.1 ml of serum was added to 0.5 ml of each substrate (4 mM α -oxoglutarate, 100 mM Phosphate buffer pH 7.4, and either 80 mM D-alanine or DL-aspartate). The reaction mixture was incubated for 30 min for both ALT and AST at 37° C. Then, 0.5 ml of 2 mM 2, 4-dinitrophenylhydrazine was added to the reaction mixture. After 20 min at room temperature, the color was developed by addition of 5.0 ml of NaOH (0.4 mol/L) and the product was read at 546 nm.

Alkaline phosphatase activity was determined by the enzymatic colorimetric method of **Kind and King**, [27]. The phenol liberated was measured in the presence of amino-4-antipyrine and potassium ferricyanide. The presence of sodium arsenate in the reagent stops the enzymatic reaction.

2.5. Assessment of histological & histopathological examinations:

For histological & histopathological examinations small pieces of the liver were fixed in 10% neutral formalin & prepared for Hematoxylin & Eosin stain, and trichrome stain [22] which stains the fibrous tissue. For histochemical study, other specimens were fixed in alcoholic bouin's fluid for glycogen demonstration using periodic acid Schiff's (PAS) technique [23].

2.6. Statistical analysis

Data were represented as mean \pm SEM. Significant differences between groups were tested using GraphPad InStat (Graph software Inc., V 3.05, Ralph Stahlman, Purdue University, Lafayette, IN).

Appropriate graphs were plotted using Prism 5 software, version 5.00 (GraphPad Software, San Diego, CA, USA). ANOVA test was used to draw comparisons between groups. P value less than 0.05 was considered statistically significant.

3. Results

3.1. Biochemical parameters evaluation:-

a. Effect of Uranium or lead intoxication hazard on the hepatic oxidative/antioxidant criterion:-

Table 1 and (Fig. 1) show the deleterious effects of uranium and lead intoxication on the hepatic oxidative/antioxidant criterion. Oral administration of lead acetate and uranium acetate at a dose of 50 and 40 mg/kg body wt. respectively, for 45 days (every other day) caused significant rise ($p < 0.01$) in hepatic MDA (116.2%) and (129.4%) for lead and uranium groups respectively as compared to control group. and significant decrease ($p < 0.01$) in GSH (-29.7%) and (-32.9%) for lead and uranium group respectively as compared to control group. In addition to, hepatic CAT was significantly decreased ($p < 0.01$) by (-28.8%) and (-37.0%) for lead and uranium group respectively as compared to control untreated rats.

b. Assessment of liver injury markers:-

The results revealed that the hazards of intoxication of rats with lead and uranium has affected the liver. This was denoted through a significant increase ($P < 0.01$) in the activity of both serum AST (87.5%) & (96.0%) , ALT (83.8%) & (104.5%) and ALP (104.5%) & (139.4%) liver

enzymes, respectively compared to their respective values in the control rats as shown in (Table 2) and (Figure 2).

3.2. Histopathological Observations:-

Hepatic specimens obtained from the control group showed a normal architecture of hepatic tissue with normal hepatocytes each cell is polygonal with a large rounded vesicular nucleus inside an acidophilic cytoplasm. These hepatocytes are arranged in cords radiating from the central vein and are separated by irregular sinusoids (Figure 3, Group1: C). Specimens taken from rats given 50 mg/kg body weight of lead acetate solution in drinking water for 45 days showed moderate parenchymatous degeneration of hepatocyte with mild congested portal vein, mild sinusoidal, pyknotic cells, and slight leucocytes infiltration (Figure 3, Group2: Pb)). Specimens examined from liver sections taken from rats exposed for 40 mg/kg body weight of Uranyl acetate in drinking water for 45 days showed parenchymatous degeneration of hepatocyte with severe congested portal vein with thickened hyalinized wall, many mitotic cell and leucocytes infiltration (Figure 3, Group3: U).

Table 1: Evaluation of antioxidant parameters MDA, GSH contents and CAT activity in the liver tissue of rats exposed to Uranium or lead.

Groups		MDA (nmol/mg tissue)	GSH ($\mu\text{g}/\text{mg}$ tissue)	CAT ($\mu\text{mol H}_2\text{O}_2/\text{min}/\text{g}$)
Control	Mean	84.64	23.7	5.47
	$\pm\text{SE}$	± 5.62	± 1.92	± 0.43
Lead	Mean	182.5 a'	16.72 a'	3.88 a'
	$\pm\text{SE}$	± 8.52	± 1.3	± 0.28
	% of change	(+116.2%)	(-29.7%)	(-28.8%)
Uranium	Mean	194.2 a'	14.95 a'	3.46 a'
	$\pm\text{SE}$	± 9.5	± 1.0	± 0.24
	% of change	(+129.4%)	(-32.9%)	(-37.0%)

- Each value represents the mean \pm SE of 10 Rats in each group.

a= $P < 0.05$ & a'= $P < 0.01$; Significantly different from control group.

% of change: % of change from the control.

Table 2: Evaluation of serum enzyme markers indicative of hepatocellular damage in rats exposed to Uranium or lead.

Groups		AST (U/L)	ALT (U/L)	ALP (U/L)
Control	Mean	32.5	27.9	70.6
	$\pm\text{SE}$	± 2.1	± 1.92	± 4.6
Lead	Mean	61.2 a'	50.8 a'	144.2 a'
	$\pm\text{SE}$	± 4.4	± 3.98	± 9.7
	% of change	(87.5%)	(83.8%)	(104.5%)
Uranium	Mean	66.4 a'	57.1 a'	168.7 a'
	$\pm\text{SE}$	± 5.2	± 4.7	± 11.5
	% of change	(96.0%)	(104.5%)	(139.4%)

Legends as in table (1).

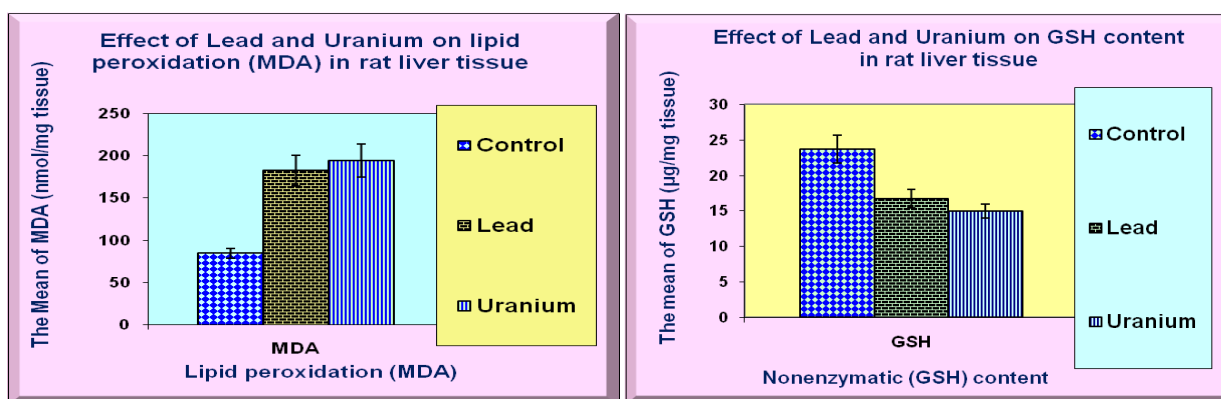


Figure 1. Showing the hazards effect of uranium or lead intoxication on the mean \pm SE of, (A) lipid peroxidation (MDA), (B) GSH content, (C) CAT activity in rat liver tissue.

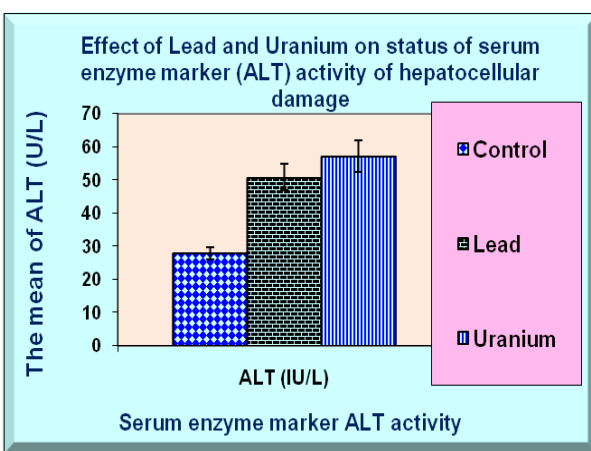
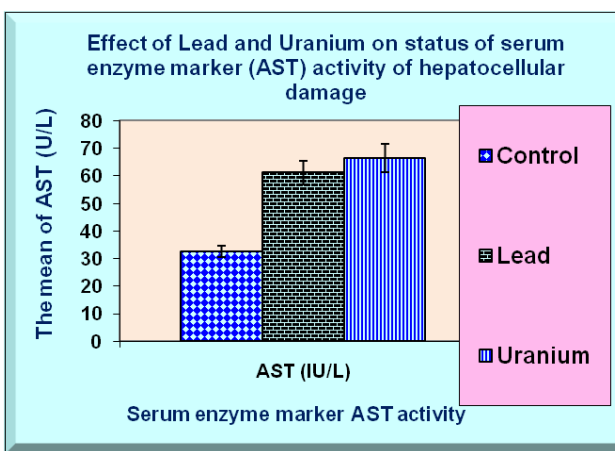
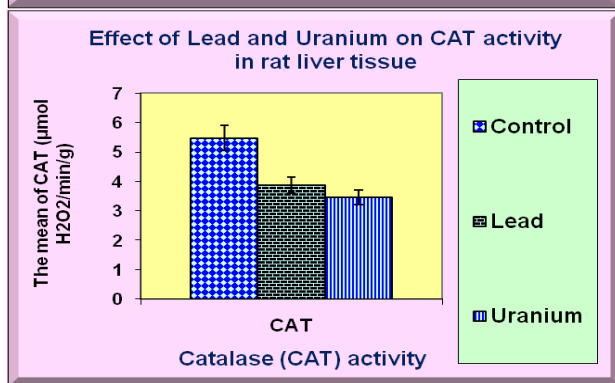
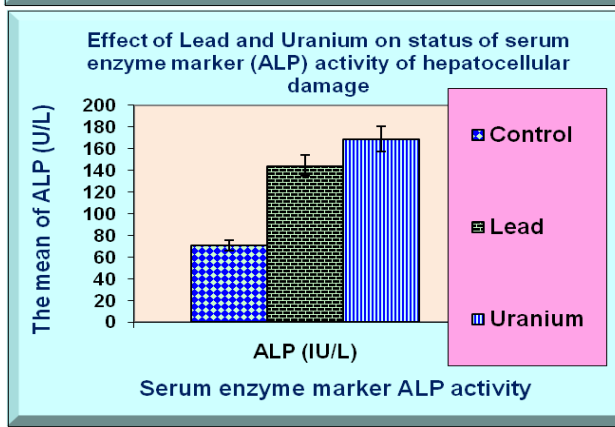


Figure 2: Showing the hazards effect of uranium or lead intoxication on the mean \pm SE of, liver enzyme markers indicative of hepatocellular damage (A) AST, (B) ALT, (C) ALP



The control liver specimen stained with Masson's trichrome showed that fibrosis, collagen fibers could not be seen, the Photomicrograph characterized in normal rats by deeply stained reddish granules in the cytoplasm of hepatocytes thin layer of normal fibrous tissue around the portal vein, which was blue in color (Figure 4, Group1: C). Specimens treated with 50 mg/kg body weight of lead acetate solution in drinking water for 45 days showed mild increase in the amount of periportal fibrous tissue

(periportal fibrosis) which is also seen radiating in between the cords of hepatic cells (Figure 4, Group2: Pb). Moreover, specimens examined after 40 mg/kg body weight of Uranyl acetate in drinking water for 45 days showed Significant increase in the area of fibrosis in liver sections (Examination Masson's trichrome stained sections showed that collagen occurred as wavy fibril either singly or fused together in dense bundles) (Figure 4, Group3: U).

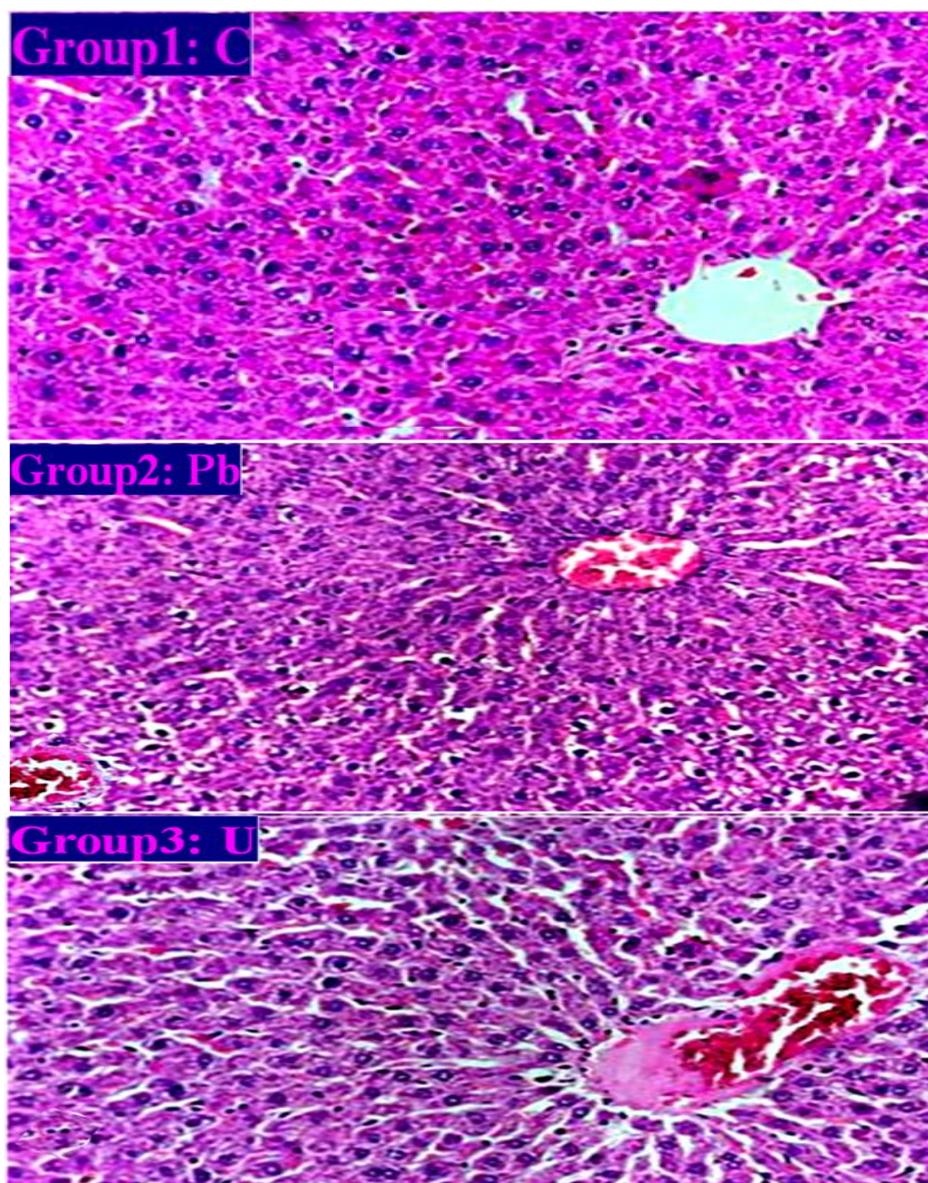


Figure 3. Photomicrograph of rats liver sections in different groups stained with hematoxylin and eosin (H&E) (x400). (Group1:C): Control rat showed normal central vein and normally arranged hepatocytes of hepatic lobule; (Group2: Pb): Rat intoxicated with lead acetate solution in drinking water 50 mg/kg body weight for 45 days showing moderate parenchymatous degeneration of hepatocyte with mild congested portal vein, mild sinusoidal, pyknotic cells, and slight leucocytes infiltration. (Group3: U): Rat intoxicated with 40 mg/kg body weight of Uranyl acetate in drinking water for 45 days showing parenchymatous degeneration of hepatocyte with severe congested portal vein with thickened hyalinized wall, many mitotic cell and leucocytes infiltration.

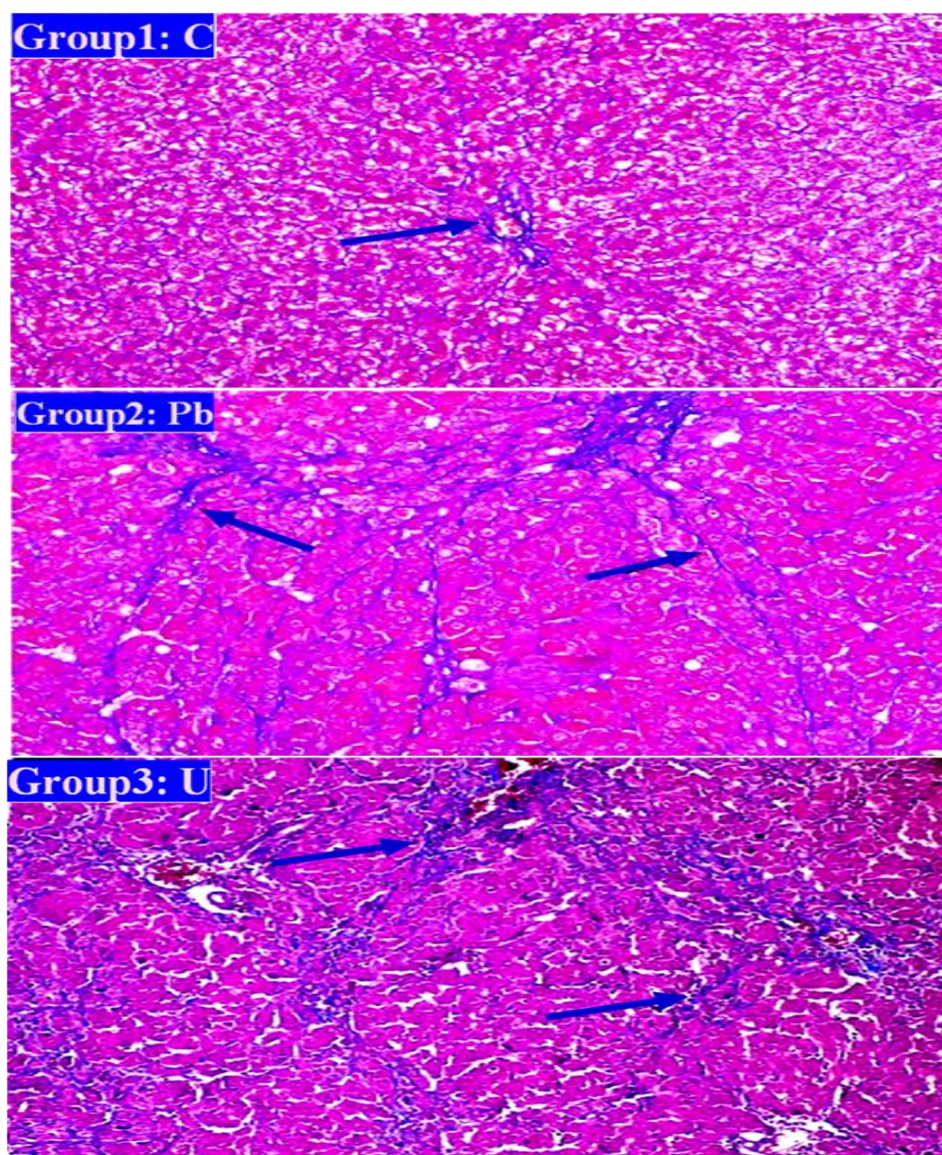


Figure 4: Photomicrograph of rats liver sections in different groups stained with Masson's trichrome staining ($\times 100$). (Group1:C): Control rat showed that fibrosis, collagen fibers could not be seen, the Photomicrograph characterized in normal rats by deeply stained reddish granules in the cytoplasm of hepatocytes. (Group2: Pb): Rat intoxicated with lead acetate solution in drinking water 50 mg/kg body weight for 45 days showing increased fibrosis, and blue collagen fibers are seen among hepatocytes and central vein (strands of blue collagen) are milder seen among hepatocytes. (Group3: U): Rat intoxicated with 40 mg/kg body weight of Uranyl acetate in drinking water for 45 days showing Significant increase in the area of fibrosis in liver sections (Examination Masson's trichrome stained sections showed that collagen occurred as wavy fibril either singly or fused together in dense bundles).

3.3. Histochemical Observations:

A control liver sample stained with PAS showed normal glycogen particles, which appeared as deep red purple PAS-positive inclusions densely located in the cytoplasm (Figure 5, Group1: C). Specimens from rats intoxicated with 50 mg/kg body weight of lead acetate solution in drinking water for 45 days showed slightly decrease of focal areas of low density of the stain denoting

carbohydrate depletion of these areas. (Figure 5, Group2: Pb). Those specimens from rats, intoxicated with 40 mg/kg body weight of Uranyl acetate in drinking water for 45 days showed decreased of focal areas of low density of the stain denoting carbohydrate depletion of these areas (although there were focal areas of low stain density indicating a decrease in carbohydrate content in these areas), (Figure 5, Group3: U).

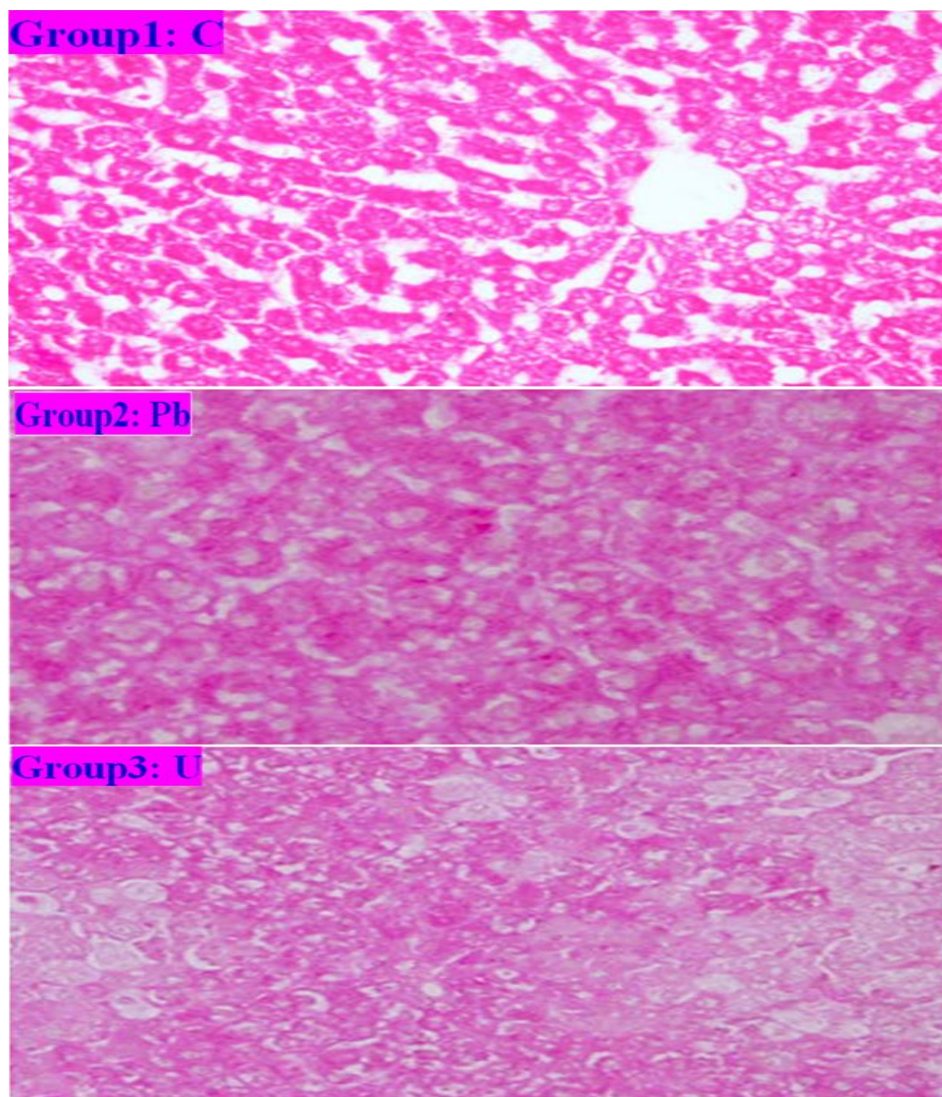


Figure 5: Shows the distribution of glycogen content in liver tissue stained by Periodic acid-Schiff's reagent (PAS) reagent. (Group: C) Control rat showed deeply stained reddish granules in the cytoplasm of hepatocytes; (Group: Pb) Rat treated with lead acetate solution in drinking water 50 mg/kg body weight for 45 days showing slightly decrease of focal areas of low density of the stain denoting carbohydrate depletion of these areas. (Group: U) Rat treated with 40 mg/kg body weight of Uranyl acetate in drinking water for 45 days showing decreased of focal areas of low density of the stain denoting carbohydrate depletion of these areas (although there were focal areas of low stain density indicating a decrease in carbohydrate content in these areas).

4. Discussion

Depleted uranium (DU) is the by-product of uranium (^{235}U) enrichment from natural uranium, as having ^{235}U content lower than 0.7112%, which emits α and β particles with high linear energy transfer. Hence, DU has the dual effects of radioactive toxicity and heavy metal toxicity, with heavy metal toxicity pre-dominating [28]. Owing to its efficient penetration and affordability, DU has recently been widely used in counterweights, radiation protection and military activities (such as armor material and ammunition components) [29]. However, unregulated

release of DU into the environment could become a threat to human health [30, 31].

The chemical toxicity of acute, high DU doses especially targets the kidneys and liver, causing severe renal tubular necrosis and hepatotoxicity [32]. Although low-dose chronic exposure to DU may not lead to clear clinical symptoms in the kidneys and liver tissues, it can cause harmful effects elsewhere, including abnormalities in neural activity, immunotoxicity and liver toxicity [33, 34]. In addition to the dose of exposure, the biological effects

of DU are affected by the exposure duration, the exposure pathway and many other factors [35].

Briner [36] proposed that lead and DU have many physical and biochemical properties, indicating the usefulness of lead as a model in DU research. In addition to automotive and industrial sources, cottage industries and the burning of paper products, discarded rubber, battery casings and painted woods for cooking and heating represent additional hazards to individual households. Lead paint, lead solder and lead cosmetics are unregulated in some countries [37]. Lead is poison that affects virtually every system in the body. Children are more vulnerable to lead exposure than adults because of the frequency of pica, hand- to -mouth activity, and a greater rate of intestinal absorption and retention. Lead has a potential preferential susceptibility of the highly vascularized organs and organized compartments [38].

The mechanism of lead or uranium causing liver toxicity is not very clear. Results from some recent studies intensely propose that oxidative stress and cellular apoptosis are the main causes for hepatic pathophysiology [32, 39, 40]. In the present study, liver specimens taken 6 weeks after exposure to Uranium and lead showed small inflammatory cellular infiltration and starting vacuolation of hepatocytes, despite this picture is not characteristic for lead or uranium poisoning, it reflected the body burden imposed by administration of a poisonous substance. This goes in hand with **Briner**, and **Gunawan & Kaplowitz**, who stated that most adverse hepatic reactions to xenobiotics require metabolism of the drug to reactive metabolites and free radicals, which then either lead or uranium to direct overwhelming lethal insult, nonlethal sensitization to the lethal effects of the innate immune system, or haptization eliciting an immunoallergic response of the adaptive [32, 41]. Immune system manifested by inflammatory cellular infiltration and activation of apoptotic systems. The results in this study go in hand with **Pal et al.**, and **Tissandie et al.** who stated that lead and uranium has been reported to cause liver injury and increase of liver enzymes markers and cellular apoptosis [42,7].

Some liver cells in lead or uranium poisoned rats showed cytoplasmic vacuoles, nuclear pyknosis and complete cell necrosis. Such a change was previously demonstrated by **Bennett, Corpas**, and **Miller et al.** [43, 44, 2]. Also, these histological picture coincided with that detected in an avian study conducted by **Kertesz & Fancsi** and **Tissandie et al.** who reported that the liver of ducklings exposed to surface water pollution with lead or uranium and other heavy metals showed significant lesions, dystrophy in the form of hepatic necrosis was detected in each treated animal [45, 7].

In our study, liver specimens showed irregular hepatocytes, with obvious periportal fibrosis and obvious vacuolar degeneration, and reduced glycogen content, especially in patients who received long-term lead or uranium treatment. In the impaired liver, diminished glycogen stores, resulting in failure of the liver to supply glucose in the post-absorptive state will likely to cause further decrease in hepatocyte viability. **Russo et al.** studied the effects of lead on the kidney and liver of rats taking lead acetate in drinking water for up to 6 months, and reported that the damage of lead to the liver was mainly confined to the central area of the lobules [46]. Endothelial cells and Kupffer cells are most affected; they often isolate large numbers of particles. In parenchymal cells, there are few particles, mainly in vesicles, but more widely distributed in the cytoplasm.

Ellender & Ham studied the effect of lead on connective tissue and reported that the local damage caused by lead is characterized by changes in granulation tissue and similar connective tissue. Granulation tissue contains various forms of mononuclear phagocytes [47]. Some cells with nuclear inclusion bodies and the granulation tissue matrix contain collagen fibers with a wide range of diameters, indicating that collagen biosynthesis has changed. The focal point of collagen mineralization occurs in the joint area of wound and lead impregnation. These foci, once mineralized became enveloped by giant cells and epitheloid cells.

These studies could explain the reported periportal fibrosis and hepatocyte disfigurement recorded in our study. Moreover, specimens stained with PAS showed mild depletion of glycogen content after exposed to lead and moderate depletion after exposed to uranium. The toxic effects of lead or uranium on the liver detected by the light microscope in the present study agreed with **Villa et al.**, and **Al Kaddissi et al.** who studied the toxic effect of lead and uranium on the liver of rats and they reported that lesions and lead or uranium deposits confirmed that lead or uranium are the causative agents [48, 1]. Correspondingly, **Corpas et al.**, and **Valko et al.** studied the effects of lead and uranium on hepatic and renal tissue of rats intoxicated with lead or uranium and reported that lead or uranium intranuclear bodies and cytoplasmic vacuoles [44, 8].

Papaioannou et al. reported that nuclear inclusion bodies are the most characteristic and specific findings induced by lead poisoning [49]. They described lead inclusion bodies as bodies with a dense central core enveloped in a cortex of matted and radiating filaments and found them in all their sacrificed rats. In our study, we observed such inclusion bodies in the juxta nuclear cytoplasm adjacent and outside the nuclear membrane as evident by ultrastructural examination of the specimens examined after the uranium administration.

Villa et al., demonstrated that, These inclusion bodies are attributed to the liver and spleen specimens of rats exposed to lead poisoning doses, because these organs are thought to contain a large number of constant macrophages with phagocytic function [48]. **Ceruti et al.**, reported characteristic histological alterations ascribed to lead in wild rats exposed to high levels of lead and reported that the incidence of intranuclear inclusion bodies and karyocytomegaly was higher in rats with high lead levels and in those exposed to lead for longer durations [50]. **Goering & Fowler**, thought that inclusion bodies represent binding of lead by a binding protein that may mitigate the effects of lead on the cell's function [51]. **Jarrar & Mahmoud**, studied lead or uranium intranuclear bodies that have resulted in the kidneys of adult Wister male rats receiving lead acetate and uranium acetate in their diet using histological and histochemical techniques to determine their nature and reported that intranuclear inclusion bodies proved to be lead lipoprotein complexes containing sulfhydryl groups and are basic in nature [52].

In the present study, the mitochondria became swollen in the uranium treated group. These results are consistent with **Faa et al.**, Prove that uranium causes hepatocyte apoptosis through a mitochondrial-dependent pathway [6].

5. Conclusion

It could be concluded that chronic exposure to lead or uranium imposes a potent toxic effect on the liver cells and architecture manifested as glycogen depletion, cellular infiltration, cellular necrosis and initiation of periportal fibrosis that may progress to liver cirrhosis.

6. Recommendations

It is recommend that, the mining or industrial companies which extract or use Uranium and lead in different Productional or industrial processes must tightly protect the workers in such places. Moreover, the environmental Uranium and/or lead pollution and uncontrolled Productional industrial use of Uranium and/or lead must be controlled.

7. References

- Al Kaddissi S, Frelon S, Elia A, Legeay A, Gonzalez P, Coppin F. "Are antioxidant and transcriptional responses useful for discriminating between chemo- and radiotoxicity of uranium in the crayfish *procambarus clarkii*?" *Ecotoxicol Environ Saf.*; 80: 266–72. (2012)
- Miller, AC. Rivas, R. Tesoro, L. Kovalenko, G. Kovaric, N. Pavlovic, P. "Radiation exposure from depleted uranium: the radiation bystander effect. *Toxicol Appl Pharm.*; 331: 135–41. (2017)
- Bleise, A. Danesi, PR. Burkart, W. "Properties, use and health effects of depleted uranium (DU): a general overview." *J Environ Radioact.*;64:93–112. (2003)
- Meinrath, A. Meinrath, G. Schneider, P. "Uranium ores and depleted uranium in the environment, with a reference to uranium in the biosphere from the Erzgebirge/Sachsen. Germany." *J Environ Radioact.*;64: 175–93. (2003)
- Di Lella, LA. Nannoni, F. Protano, G. Riccobono, F. "Uranium contents and 235U/238U atom ratios in soil and earthworms in western Kosovo after the 1999 war." *Sci Total Environ.*;337:109–18. (2005)
- Faa, A. Gerosa, C. Fanni, D. Floris, G. Eyken, PV. Lachowicz, JI. "Depleted uranium and human health." *Curr Med Chem.*;24:1–16. (2017)
- Tissandie, E. Gueguen, Y. Lobaccaro, JMA. Paquet, F. Aigueperse, J. Souidi, M. "Effects of depleted uranium after short-term exposure on vitamin D metabolism in rat." *Arch Toxicol.*;80:473–80. (2006)
- Hensley, K. "Neuro-inflammatory aberrations of arachidonate pathway in ALS. *Neuroscience.*" *Bioachm. Biophys. Res. Commun.* **82**: 70-74. (2004).
- Valko, M. Rhodes, CJ. Moncol, J. Izakovic, M. & Mazur, M. "Free radicals, metals and antioxidants in oxidative stress induced cancer." *Chem. Biol. Interact.*; **160**: 1-40 (2006).
- McDiarmid, M. Gaitens, JM Hines, S Breyer, R. Oliver, M. Gucer, P. Squibb, KS. "The Gulf War depleted uranium cohort at 20: bioassay results and novel approaches to fragment surveillance". *Health Phys.* **104**, 347-361 (2013).
- Tissandie, E. Guéguen Y. Lobaccaro JMA. Grandcolas L. Voisin P. Aigueperse J. Gourmelon P. and Souidi M. "In vivo effects of chronic contamination with depleted uranium on vitamin D3 metabolism in rat". *Biochim. Biophys. Acta.*, **1770**, 266-272 (2007).
- Moreira, F.R. and Moreira, J.C. "Effects of Lead Exposure on the Human Body and Health Implications". *Revista Panamericana de Salud Pública*, **15**, 119-129. (2004)
- Flora G, Gupta D, Tiwari A. Toxicity of lead: A review with recent updates. *Interdisciplinary Toxicology.*; 5:47–58. (2012)
- White, LD. Cory-Slechta, DA. Gilbert, ME. TiVany-Castiglioni, E. and Zawia, NH. "New and Evolving Concepts in the Neurotoxicology of Lead". *Toxicology and Applied Pharmacology*, **225**, 1-27. (2007)
- Ahamed, M. and Siddiqui, MKJ. "Low Level Lead Exposure and Oxidative Stress: Current Opinions". *Clinica Chimica Acta*, **383**, 57-64. (2007)
- Jones, AL. "Anatomy of the Normal Liver". In: *Hepatology*, Z.D. and Boyer, T.D., Eds., *Hepatology. A Text Book of Liver Disease*, W.B. Saunders Co, Philadelphia, 3-31. (1982)

17. Bannister, L.H. "Alimentary System. In: Banister, L.H., Berry, M.M., Collis, P.P., Dyson, M., Dussek, J.E. and Ferguson, M.W., Eds., *Grays's Anatomy*, 38th Edition, Churchill Livingstone, London, 1683-812. (1995)
18. Wilczynska, U. Szeszenia-Dabrowska, N. and Sobala, W. "Mortality of Men with Occupational Lead Poisoning in Poland". *Medycyna Pracy*, **49**, 113-128. (1998)
19. Sharma, V. Sharma, S. Pracheta and Sharma S "Lead Induced Hepatotoxicity in Male Albino Mice: The Protective Potential of the Hydromeyhanolic Extract of *Withania Somnifera*". *International Journal of Pharmaceutical Sciences Review and Research*, **7**, 116-121. (2011)
20. Mahmoudzadeh Sagheb, HR. Heidari, Z. Barbarestani, M. and Noori Mugahi, MH. "Ultrastructural Study of Neutrophils in Fetal Rat Spleen Following Lead Intoxication". *Yakhteh Medical Journal*, **5**, 172-177. (2004)
21. Domingo, J.L., Llobet, J.M., Tomas, J.M. & Corbella, J. "Acute toxicity of uranium in rats and mice". *Bull. Environ. Contam. Toxicol.* **39**, 168-174 (1987).
22. McManus, J. and Mowry, R. "Staining Methods". Histological and Histochemical Harber and Row Inc., New York and London. (1963)
23. Hotchkiss, R.D. "A Microchemical Reaction Resulting in the Staining of Polysaccharide Structures in Fixed Tissue Preparations". *Archives of Biochemistry*, **16**, 131. (1948)
24. Ohkawa, H. Onishi, N. Yagi, K. "Assay for lipid peroxidation in animal tissue by thiobarbituric acid reaction. *Anal Biochem*; 95: 351-358. (1979)
25. Ellman, G.L. "Tissue sulphhydryl groups". *Arch Biochem Biophys*; 82: 70-77. (1959)
26. Aebi, H. "Catalase. In: Bergmeyer (eds). *Methods in enzymatic analysis*", NewYork, Academic Press, pp 674-684. (1974)
27. Kind, P.R. and King, E.J. "Estimation of plasma phosphatase by determination of hydrolysed phenol with amino-antipyrine. *J. Clin. Pathol*; 7: 322-326. (1954)
28. Priest ND. "Toxicity of depleted uranium". *Lancet*; 357:244-6. (2001)
29. Bleise, A. Danesi, P.R. Burkart, W. "Properties, use and health effects of depleted uranium (DU): a general overview". *J Environ Radioact* ;64:93-112. (2003)
30. Craft, E. Abu-Qare, A. Flaherty, M. Garofolo, M. Rincavage, H. Abou-Donia, M. "Depleted and natural uranium: chemistry and toxicological effects". *J Toxicol Environ Health B Crit Rev*;7:297-317. (2004)
31. Hindin, R. Brugge, D. Panikkar, B. "Teratogenicity of depleted uranium aerosols: a review from an epidemiological perspective". *Environ Health*;4:17. (2005)
32. Briner W. "The Toxicity of Depleted Uranium". *Int J Environ Res Public Health*;7:303-13. (2010)
33. Lu, S. Zhao, F.Y. "Nephrotoxic limit and annual limit on intake for natural U". *Health Phys*;58:619-23. (1990)
34. Tissandié, E. Guéguen, Y. Lobaccaro, J.M. Grandcolas, L. Voisin, P. Aigueperse, J. " In vivo effects of chronic contamination with depleted uranium on vitamin D3 metabolism in rat. *Biochim Biophys Acta*;1770:266-72. (2007)
35. Racine, R. Gueguen, Y. Gourmelon, P. Veysiere, G. Souidi, M. "Modifications of the expression of genes involved in cerebral cholesterol metabolism in the rat following chronic ingestion of depleted uranium". *J Mol Neurosci*;38:159-65. (2009)
36. ATSDR (Agency for Toxic Substances aDR). *Toxicological Profile for Uranium*. US Public Health Services, Washington, DC, (1999).
37. Briner, W.E. "The evolution of depleted uranium as an environmental risk factor: lessons from other metals". *Int J Environ Res Public Health*;3:129-35. (2006)
38. Srianjata, S. "Lead-The Toxic Metal to Stay with Human. *The Journal of Toxicological Sciences, Suppl.* **2**, 237- 240. (1998)
39. Sharma, V. and Pandey, D. "Protective Role of *Tinospora ordifolia* against Lead-Induced Hepatotoxicity". *Toxicology International*, **17**, 12-17. (2011)
40. Clement, G.Y. and Paul, B.T. "N-Acetyl-L-Cysteine Affords Protection against Lead-Induced Cytotoxicity and Oxidative Stress in Human Liver Carcinoma (HepG2) Cells". *International Journal of Environmental Research and Public Health*, **4**, 132-137. (2007)
41. Gunawan, B. and Kaplowitz, N. "Clinical Perspectives on Xenobiotic-Induced Hepatotoxicity". *Drug Metabolism Reviews*, **36**, 301-312. (2004)
42. Pal, P.B., Sinha, K. and Sil, P.C. "Mangiferin, a Natural Xanthone, Protects Murine Liver in Pb (II) Induced Hepatic Damage and Cell Death via MAP Kinase, NFkB and Mitochondria Dependent Pathways". *PLoS One*, **8**, Article ID: e56894. (2013)
43. Bennett, W.M. "lead Nephropathy". *Kidney International*, **28**, 12-20. (1985)
44. Corpas, I. Benito, M.J. and Antonio, M.T. "Hepatic and Renal Alterations in Newborn Rats Induced by Prenatal and Early Lactational Exposure to Lead and/or Cadmium". *Reviews in Toxicology*, **13**, 76-82. (1996)
45. Kertesz, V. and Fancsi, T. "Adverse Effects of (Surface Water Pollutants) Cd, Cr and Pb on the Embryogenesis of the Msallard". *Aquatic Toxicology*, **65**, 425-433. (2003)
46. Russo, M.A., Kapoor, S.C. and van Rossum, G.D. "Localization of Lead in the Kidney and Liver of Rats Treated *in Vivo* with Lead Acetate:

- Ultrastructural Studies on Unstained Sections". *British Journal of Experimental Pathology*, **69**, 221-234. (1988)
47. Ellender, G. and Ham, KN. "Connective Tissue Responses to Some Heavy Metals. I. Sodium Loaded Ion Exchange Beads as a Control: Histology and Ultrastructure". *British Journal of Experimental Pathology*, **68**, 277-289. (1987)
48. Villa, N.R., Mercou, G., Riera, N.M., Santos, N.S. and Vitalone, H. "Lead: Histopathological Findings in Experimental Contamination". *Acta Gastroenterol Latinoam*, **23**, 159-163. (1993)
49. Papaioannou, N., Vlemmas, I., Balaskas, N. and Tsangaris, Th. "Histopathological Lesion in Lead Intoxicated Dogs". *Veterinary and Human Toxicology*, **40**, 203-207. (1998)
50. Ceruti, R. Ghisleni, G. Ferretti, E. Cammarata, S. Sonzogni, O. and Scanziani, E. "Wild Rats as Monitors of Environmental Lead Contamination in the Urban Area of Milan, Italy". *Environmental Pollution*, **117**, 255-259. (2002)
51. Goering, PL. and Fowler, BA. "Mechanism of Renal Lead-Binding Protein Reversal of Delta-Aminolevulinic Acid Dehydratase Inhibition by Lead". *Journal of Pharmacology and Experimental Therapeutics*, **234**, 365-371. (1985)
52. Jarrar, B.M. and Mahmoud, Z.N. "Histochemical Characterization of the Lead Intranuclear Inclusion Bodies". *Biological Trace Element Research*, **75**, 245-251. (2000)