



## Anti-inflammatory role of *Dunaliella salina* carotenoid enrich fractions in paw oedema via down-regulation of COX-2/PGE2 pathway



Farouk K. El-Baz<sup>1</sup>, Ahmed M. Aboul-Enein<sup>2</sup>, Osama M. Abdel-Fatah<sup>2</sup>, Hanaa H. Abd El-Baky<sup>1</sup>, Ahmed M. Hagag<sup>1</sup>, Sami I. Ali<sup>1</sup>, Abeer Salama<sup>3</sup>

<sup>1</sup> Plant Biochemistry Department, National Research Centre, El Buhouth St., Cairo, 12622, Egypt.

<sup>2</sup> Biochemistry Department, Faculty of Agriculture, Cairo University, Egypt.

<sup>3</sup> Pharmacology Department, National Research Centre, El Buhouth St., Cairo, 12622, Egypt.

### Abstract

*Dunaliella salina* (*D. salina*) is rich in natural potent antioxidants as beta carotene and zeaxanthin. It exhibits several therapeutic effects for diabetes, cancer, eye, and cardiovascular disorders. This study assesses the anti-inflammatory effect of beta carotene and zeaxanthin enrich fractions of *D. salina* against carrageenan induced inflammation in rats. HPLC analysis was performed, inflammation and oedema was induced by 1% carrageenan. Crude extract of *Dunaliella salina* and carotenoids enrich fractions; zeaxanthin and  $\beta$ -carotene were administered orally concurrent with carrageenan. Paw thickness was measured at  $t = 1, 2, 3$  and 4 hours. Oxidative stress biomarkers; nitric oxide (NO), malondialdehyde (MDA) and catalase, proinflammatory cytokines; tumor necrosis factor-alpha (TNF- $\alpha$ ), interleukin-6 (IL-6), cyclooxygenase-2 (COX-2), prostaglandin E2 (PGE2) and neurotransmitters as serotonin were performed on serum samples. The HPLC analysis showed that crude extract contains  $\beta$ -carotene (19.167 mg/g extract) and zeaxanthin (16.196 mg/g extract), while beta carotene enrich fraction contains  $\beta$ -carotene (43.157 mg/g fraction) and zeaxanthin enrich fraction contains  $\beta$ -carotene (22.015 mg/g fraction). *D. salina* and carotenoids enrich fractions showed a statistically significant decrease in paw thickness at  $P < 0.05$ . *D. salina* and carotenoids rich fractions downregulated TNF- $\alpha$ , IL-6, COX-2, PGE2 and serotonin. *D. salina* and carotenoids enrich fractions ameliorated carrageenan inflammatory reaction by suppressing the oxidative stress and proinflammatory cytokines pathway

**Keywords:** *Dunaliella salina*;  $\beta$ -carotene; zeaxanthin; carrageenan; COX-2; PGE2

### 1. Introduction

Standards and samples were pipetted into wells with immobilized antibodies specific for rat TNF- $\alpha$ , IL-6, COX-2 and PGE2 and then were incubated 30 min at 37°C. After incubation and washing, horseradish peroxidase-conjugated streptavidin was pipetted into the wells and incubated 30 min at 37°C, which were washed once again. TMB (tetramethylbenzidine) substrate solution was Inflammation is a common cause in the acute and chronic debilitating diseases and if unchecked, leads to rheumatoid arthritis, cancer, diabetes, Alzheimer's disease, and pulmonary, cardiovascular and autoimmune diseases. Inflammation provokes a network of several mediators, and execution of many pathways<sup>1, 2</sup>. Nonsteroidal anti-inflammatory drugs as indomethacin, aspirin, naproxen and ibuprofen<sup>3</sup> or steroidal anti-inflammatory-immunity drugs as glucocorticoid<sup>4</sup> have side effects including hepatotoxicity, gastrointestinal injury, obesity, and osteoporosis<sup>5</sup>. Therefore, it is necessary to discover

new natural effective and safe compounds for anti-inflammatory therapy.

Carotenoids, one of the most prevalent natural pigments, are having considerable health benefits. They contain a  $\beta$ -ionone ring that acts as precursors of vitamin A and as powerful antioxidants through lipid peroxidation suppression<sup>6</sup>. They are improving the immune system, ameliorating the inflammation-related cardiac dysfunction, and enhancing the recovery from age-related diseases. They are lipid-soluble components with yellow to red color range, synthesized in large quantities in microalgae *Dunaliella salina* as a photoprotector against excessive light<sup>7, 8</sup>.

*D. salina* is a type of unicellular biflagellate microalga and is a photoautotrophic and salt-tolerant microalga, lacking the outer solid cell wall<sup>9</sup>. Beta carotene ( $\beta$ -carotene) and zeaxanthin are the most carotenoids produced in *D. salina* in high amounts<sup>10</sup>.  $\beta$ -carotene is well-known natural antioxidants through protecting human cells against free radicals

\*Corresponding author e-mail: [berrotec@yahoo.com](mailto:berrotec@yahoo.com); (Abeer Salama).

Receive Date: 07 July 2021, Revise Date: 31 July 2021, Accept Date: 08 August 2021

DOI: 10.21608/EJCHEM.2021.84702.4135

©2022 National Information and Documentation Center (NIDOC)

induced dysfunction especially singlet oxygen<sup>6</sup>. Divers epidemiologic investigations indicate that consumption of necessary amounts of  $\beta$ -carotene is able to reduce possibilities of different cancers especially prostate cancer<sup>11</sup>. The all-trans- $\beta$ -carotene and 9-cis- $\beta$ -carotene of *Dunaliella bardawil* suppress the development of hepatic conjugated dienes resulted from alcohol-induced oxidative stress in rats<sup>12</sup>.

Zeaxanthin is one of the oxygenated carotenoids called xanthophylls with potent antioxidant activity, and therapeutic effect against age-related macular deterioration<sup>13</sup>. It showed a positive effect on ulcerative colitis as well precancerous and cancerous colorectal damages<sup>14</sup>. Zeaxanthin is a natural carotenoid and has a potent anti-oxidant activity that protects the retina from light-induced damage. It has been observed that its consumption with higher levels in diets are associated with low incidence of eye diseases, stroke and coronary heart disease<sup>15</sup>. Zeaxanthin of *D. salina* improves age related cardiac dysfunction through upregulation of retinoid receptors in rats<sup>10</sup>. To the best of our knowledge, this is the first study to evaluate the anti-inflammatory effect of carotenoid enrich fractions of *D. salina* microalgae; zeaxanthin and  $\beta$ -carotene against carrageenan in rat and the mechanism of their actions.

## 2. Material and methods

### Cultivation of *D. salina*

*D. salina* was isolated from salt deposition basins of The Egyptian Salts and Minerals Company, EMISAL and grown on Bold media<sup>16</sup> containing NaCl with a concentration of 100 g/l. The algal biomass was harvested and inoculated in plastic bottles with a capacity of 17 l containing 15 l of microalgae culture with continuous aeration. After growing for 10 days the culture was transferred to a fully automated and computer controlled photobioreactor with the capacity of 4000 l. Carbon dioxide was injected into the culture as a carbon source. The culture was left to grow until the biomass reached 2–2.5 g/l. Algal biomass was harvested by centrifugation at 2000 rpm and then sun-dried at 40–45°C. The dried biomass of *D. salina* was ground thoroughly for cell wall disruption.

### Preparation of algal extract

The fine powder of *D. salina* (100 g) was soaked with 1000 ml of hexane/ethyl acetate (1:1, V/V) in 2000 ml conical flask and kept on an orbital shaker (Stuart, England) at 160 rpm at room temperature for 24 h. Then, the extract was centrifuged (Sigma 3-18ks Centrifuge, Germany) at 5000 rpm for 20 min at 25°C to separate cell debris from the supernatant. The extraction step was repeated twice and the pooled supernatants were concentrated using a

vacuum rotary evaporator (Heidolph Unimax 2010, Germany) at 40°C to dryness giving the crude extract. The crude extract was subjected to a silica gel column chromatography using silica gel, 60-120  $\mu$ m (Sigma-Aldrich Co., USA) and hexane/ethyl acetate as mobile phase with increasing polarity (0, 10, 20, 30, 50, 70, and 100% ethyl acetate) that afforded 21 fractions that collected in 50 ml per each fraction. The 21 fractions were subjected to TLC (20  $\times$  20 cm aluminum sheets coated with silica gel 60 F254, Merck, Germany) to detect the presence of Phyto-compounds that visualized by ultraviolet (UV) fluorescent colors at 254/366 nm UV lamps. Fractions were combined to 6 fractions (1-6) based on TLC results and concentrated to dryness using a rotary evaporator.  $\beta$ -carotene enriches fraction (Fraction 1) and zeaxanthin enriches fraction (Fraction 5) were confirmed by HPLC. All the extraction and column chromatography fractionation steps were performed in dim light.

### HPLC analysis of beta carotene and zeaxanthin

*D. salina* crude extract and beta carotene and zeaxanthin enrich fractions were subjected to An Agilent 1260 infinity series HPLC-DAD system (Agilent Technologies, Germany) equipped with binary gradient Agilent 1260 prep pump (G1361A), an auto sampler Agilent 1260 prep ALS (G2260A), and Agilent diode array detector 1260 DAD VL (G1315D) was employed for the detection of the separated  $\beta$ -carotene and zeaxanthin. Agilent 5 Prep-C18 Scalar column (5  $\mu$ m, 150 mm  $\times$  4.6 mm) was utilized for separation. The following solvents were used at a flow rate of 1.25 ml/min: (A) acetone and (B) methanol: H<sub>2</sub>O (9:1 v/v) containing 0.05% BHT. The separation of  $\beta$ -carotene and zeaxanthin was achieved by a gradient between solvents A and B for 40 min as follows: B was run at 80 to 20% for 25 min, 20% for 10 min, and 20 to 80% for 5 min<sup>17</sup>. The peaks were integrated at 450 nm to quantify  $\beta$ -carotene and zeaxanthin.  $\beta$ -carotene and zeaxanthin (Sigma-Aldrich Co., USA) were used as standard.  $\beta$ -carotene and zeaxanthin were identified and quantified through comparing retention time and the peak area of the unknown peak with the  $\beta$ -carotene and zeaxanthin standards.

### Animals

Fifty adult male Wister albino rats (7-8-weeks old, weighing 130-150 g) were housed in standard cages (10 rats/cage), and maintained at controlled room temperature (21-24°C) with a 40-60% relative humidity and under normal dark–light cycles. All animals had free access to rat chow diet and water *ad libitum* and were acclimated for two weeks prior to initiation of the experiment in the laboratory in the National Research Centre. All procedures were

approved by the Animal Care Committee of the National Research Centre.

### Carrageenan induced paw Oedema

Paw swelling was elicited by sub-plantar injection of 100  $\mu$ l of 1% sterile lambda carrageenan suspension in saline into the right hind paw<sup>18</sup>. Contralateral paw received an equal volume of saline. The oedema component of inflammation was quantified by measuring hind footpad before carrageenan injection<sup>19</sup>. and 1- 4 h after carrageenan injection with a micrometer caliber<sup>20, 21</sup>. Oedema was expressed as a percentage of change from control (pre-drug) values. Rats were divided into 5 groups each of ten. 1st group: Rats received orally saline (0.2 ml /rat) and served as normal control, 2nd group: Rats were injected with carrageenan and served as carrageenan control, 3rd group: Rats received crude extract (200 mg/kg) 1 h before carrageenan<sup>22</sup> 4<sup>th</sup> group: Rats received zeaxanthin (30 mg/kg) 1 h before carrageenan. 5<sup>th</sup> group: Rats received  $\beta$ -carotene (30 mg/kg) 1 h before carrageenan<sup>23</sup>

### Preparation of blood samples for biochemical analysis.

1 h and 4 h following carrageenan injection, blood samples were withdrawn from rats of all groups via retro-orbital vein under anesthesia with phenobarbital sodium. Oxidative stress biomarkers; nitric oxide (NO), malondialdehyde (MDA) and catalase, proinflammatory cytokines; tumor necrosis factor-alpha (TNF- $\alpha$ ), interleukin-6 (IL-6), cyclooxygenase-2 (COX-2), prostaglandin E2 (PGE2) and neurotransmitters as serotonin were estimated in serum using specific ELISA kits. Immediately after blood sampling, animals were sacrificed by cervical dislocation<sup>24</sup> under anaesthesia with pentobarbital sodium. Hind paw from each rat was immediately dissected out, and rinsed with PBS.

### Determination of oxidative stress biomarkers

In acid medium and in the presence of nitrite the formed nitrous acid diazotise sulphanilamide and the product is coupled with N-(1-naphthyl) ethylenediamine. The resulting azo dye has a bright reddish – purple color which measured at 540 nm, using Biodiagnostic kits, Egypt. In addition, MDA measured using Biodiagnostic kits, Egypt and Catalase reacts with a known quantity of H<sub>2</sub>O<sub>2</sub>. The reaction is stopped after exactly one minute with catalase inhibitor. In the presence of peroxidase (HRP), remaining H<sub>2</sub>O<sub>2</sub> reacts with 3,5-Dichloro -2-hydroxybenzene sulfonic acid (DHBS) and 4-aminophenazone (AAP) to form a chromophore with a color intensity inversely proportional to the amount of catalase in the original sample using Biodiagnostic kits, Egypt.

### Determination of inflammatory biomarkers

Serum level of TNF- $\alpha$ , IL-6, COX-2 and PGE2 were determined using the manufacturer's instructions of Elabscience, China, ELISA (Enzyme-Linked Immunosorbent Assay) kits (Catalog No. E-EL-R0019), (Catalog No. E-EL-R0015), (Catalog No. E-EL-R0034) and Abnova, USA (Catalog No. KA4522) ELISA kit, respectively, for calculating the results added to the wells and incubated 15 min at 37°C; color developed proportionally to the amount of TNF- $\alpha$ , IL-6, COX-2 and PGE2 bound. Color development was discontinued (Stop Solution) and after 10 min color intensity was measured at 450 nm<sup>25</sup>.

### Determination of serotonin

Serum level of Serotonin was determined using the manufacturer's instructions of LifeSpan sciences, China, ELISA kit for calculating the results (Catalog No. LS-F28152). Standards and samples were pipetted into wells with immobilized antibodies specific for rat serotonin and then were incubated 30 min at 37°C. After incubation and washing, horseradish peroxidase-conjugated streptavidin was pipetted into the wells and incubated 30 min at 37°C, which were washed once again. TMB (tetramethylbenzidine) substrate solution was added to the wells and incubated 15 min at 37°C; color developed proportionally to the amount of Serotonin bound. Color development was discontinued (Stop Solution) and after 10 min color intensity was measured at 450 nm.

### Histological examination

At the end of the experiment, paw was removed carefully and fixed in 10% formalin for 24 hours, washed under tap water, dehydrated in ascending grades of ethanol (50, 70, 80, 90, and 100%), cleared in xylene, and embedded in paraffin wax. paw sections of 5  $\mu$ m thickness were prepared and stained with haematoxylin and eosin.

### Statistical analysis

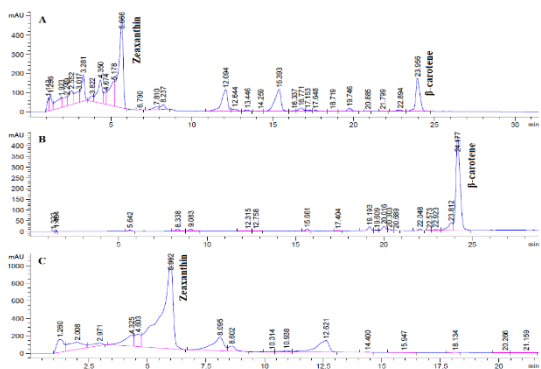
All the values are presented as means  $\pm$  standard error of the means (SE). Comparisons between different groups were carried out using one-way analysis of variance (ANOVA) followed by Tukey's multiple comparisons test. Graphpad Prism software, version 5 (Inc., USA) was used to carry out these statistical tests. The difference was considered significant when  $p < 0.05$ .

## 3. Results

### HPLC analysis of beta carotene and zeaxanthin

The extraction of fine powder of *D. salina* with hexane/ethyl acetate (1:1, V/V) revealed crude extract with extraction yield (2.16%) containing  $\beta$ -carotene (0.414 mg/g algal powder) and zeaxanthin (0.350 mg/g algal powder). The HPLC analysis

(Figure 1) showed that crude extract contains  $\beta$ -carotene (19.167 mg/g crud extract) and zeaxanthin (16.196 mg/g crude extract), while  $\beta$ -carotene enriches fraction contains  $\beta$ -carotene(43.157 mg/g fraction) and zeaxanthin enriches fraction contains zeaxanthin (22.015 mg/g fraction).



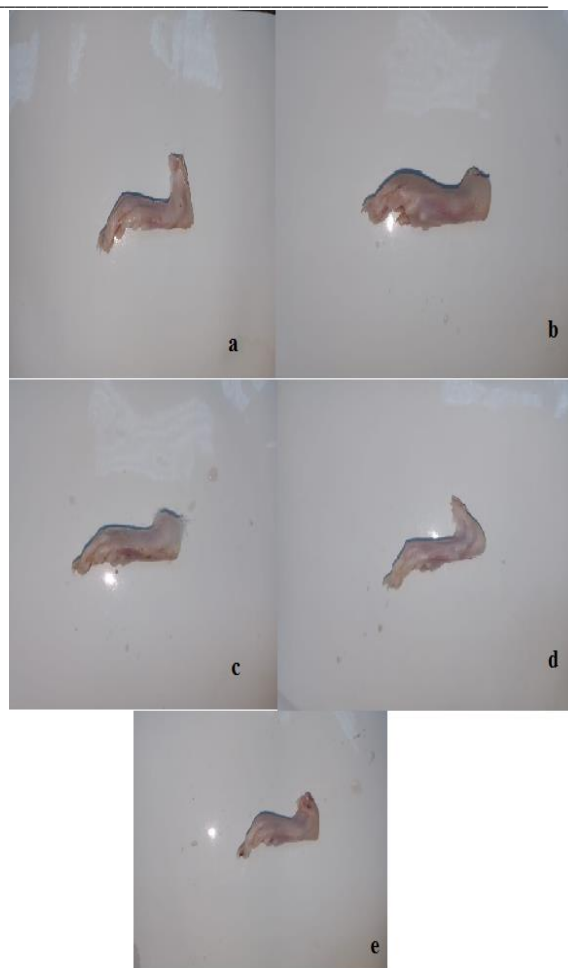
**Figure 1:** HPLC spectrum at 450 nm of  $\beta$ -carotene and zeaxanthin of *Dunaliella salina* crude extract (A),  $\beta$ -carotene enriches fraction (B), and zeaxanthin enriches fraction (C).

#### Effects of carotenoids enrich fractions of *D. salina* microalgae on carrageenan induced paw oedema

The subplanter injection of 100 $\mu$ L of 1% sterile carrageenan into the rat hind paw elicited an inflammation (swelling and erythema) and a time-dependent increase in paw oedema by 66.49%, 37.23%, 36.70% and 24.47% at 1<sup>st</sup>, 2<sup>nd</sup>, 3<sup>rd</sup> and 4<sup>th</sup> hours respectively, as compared with pre-carrageenan control values. Administration of crude extract, zeaxanthin and  $\beta$ -carotene showed a significant inhibition of oedema formation at 4<sup>th</sup> hours by 64.84%, 78.24% and 47.11%, respectively, as compared with carrageenan control group at the same time (Figure 2 & 3).

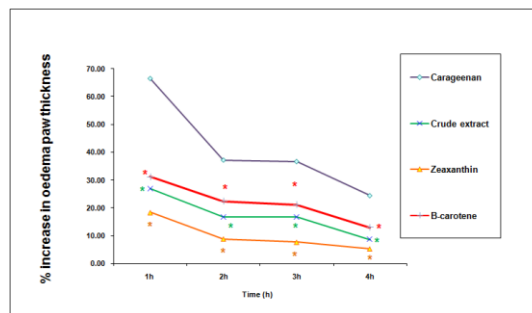
#### Effects of carotenoids enrich fractions of *D. salina* microalgae on serotonin serum levels

Carrageenan induced serotonin elevation by 35% after 1h, in serum as compared with normal control, while administration of crude extract and Zeaxanthin only showed a significant inhibition of serotonin release by 7%, and 12%, respectively, as compared with carrageenan control group. In addition administration of Zeaxanthin showed a significant inhibition of it by 5% as compared with crude extract (Figure 4).



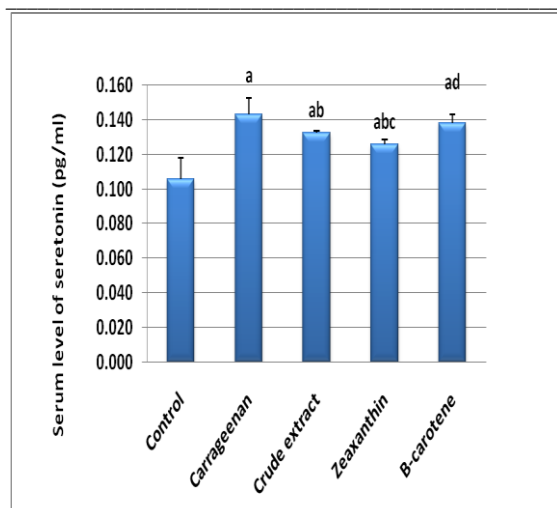
**Figure 2:** Effects of carotenoids enrich fractions of *Dunaliella salina* microalgae on paw oedema thickness

a) Control group, b) Carrageenan group, c) Crude extract group, d) zeaxanthin group, and e)  $\beta$ -carotene group



**Figure 3:** Effect of carotenoid enrich fractions of *Dunaliella salina* microalgae on rat paw oedema percentage increase

Data were expressed as mean  $\pm$  SE. Statistical analysis was carried out by one-way ANOVA followed by Tukey's multiple comparisons test. \* Significantly different from carrageenan control at  $P < 0.05$ .

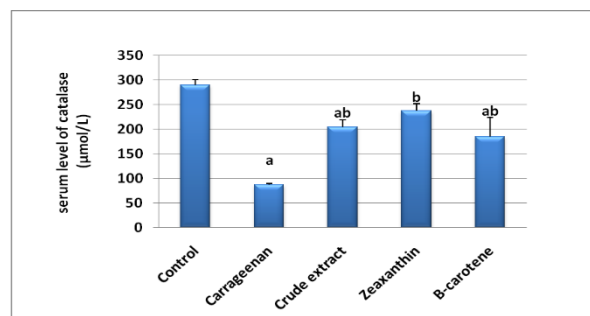
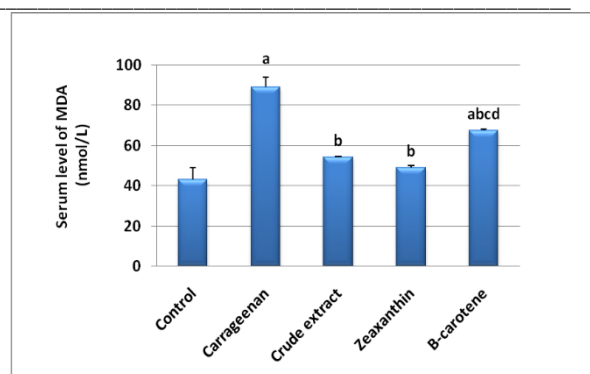
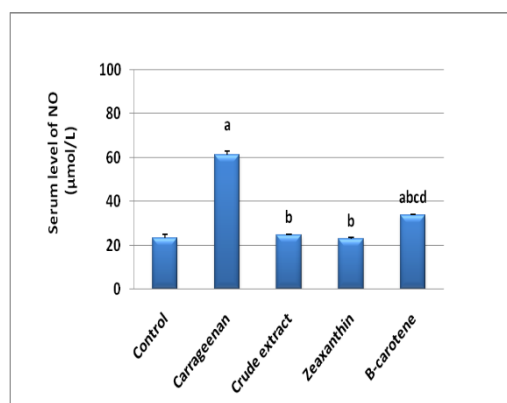


**Figure 4: Effect of carotenoid rich fractions of *Dunaliella salina* microalgae on serotonin serum level**

Data were expressed as mean  $\pm$  SE. Statistical analysis was carried out by one-way ANOVA followed by Tukey's multiple comparisons test. <sup>a</sup> Significantly different from normal control at  $P < 0.05$ . <sup>b</sup> Significantly different from carrageenan control at  $P < 0.05$ . <sup>c</sup> Significantly different from crude extract at  $P < 0.05$ . <sup>d</sup> Significantly different from zeaxanthin at  $P < 0.05$ .

#### Effects of carotenoids enrich fractions of *D. salina* microalgae on NO, MDA and catalase serum levels

Oxidative stress induced by carrageenan elevating serum levels of NO and MDA by 160% and 100% respectively, and reducing catalase serum level by 70% as compared with normal control, while administration of crude extract, Zeaxanthin and  $\beta$ -carotene showed a significant decrease of serum levels of NO by 60%, 63%, and 45%, respectively, MDA by 39%, 45% and 24%, and a significant increase of serum levels of catalase by 134%, 170% and 112% respectively, as compared with carrageenan control group. In addition administration of crude extract and zeaxanthin normalized NO and MDA while administration of Zeaxanthin only normalized catalase serum level (Figure 5).

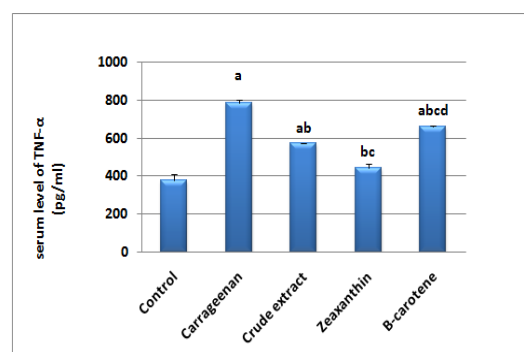


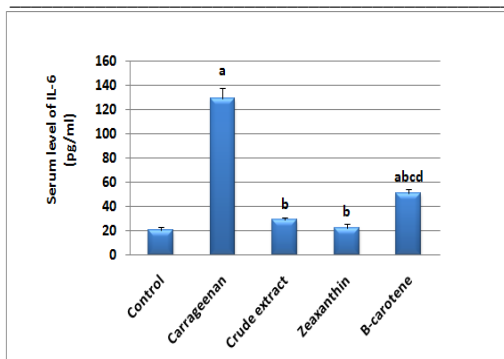
**Figure 5: Effects of carotenoids enrich fractions of *D. salina* microalgae on NO, MDA and catalase**

Data were expressed as mean  $\pm$  SE. Statistical analysis was carried out by one-way ANOVA followed by Tukey's multiple comparisons test. <sup>a</sup> Significantly different from normal control at  $P < 0.05$ . <sup>b</sup> Significantly different from carrageenan control at  $P < 0.05$ . <sup>c</sup> Significantly different from crude extract at  $P < 0.05$ . <sup>d</sup> Significantly different from zeaxanthin at  $P < 0.05$ .

#### Effects of carotenoids enrich fractions of *D. salina* microalgae on TNF- $\alpha$ and IL-6 serum levels

Carrageenan induced TNF- $\alpha$  elevation by 1 fold and IL-6 secretion by 5.2 fold in serum as compared with normal control, while administration of crude extract, Zeaxanthin and  $\beta$ -carotene showed a significant inhibition of TNF- $\alpha$  release by 27%, 43%, and 16%, respectively, and IL-6 release by 78%, 83% and 60%, respectively, as compared with carrageenan control group. In addition administration of crude extract and zeaxanthin normalized IL-6 release while administration of Zeaxanthin only normalized TNF- $\alpha$  serum level and showed a significant inhibition of it by 22% as compared with crude extract (Figure 6).



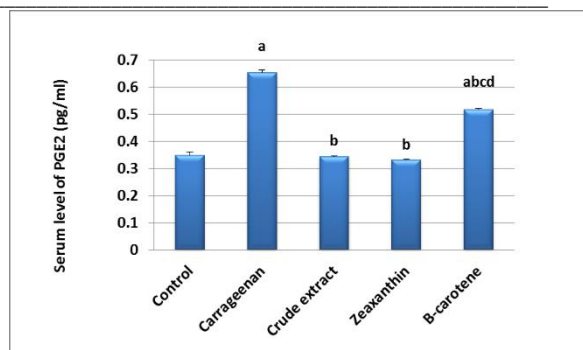
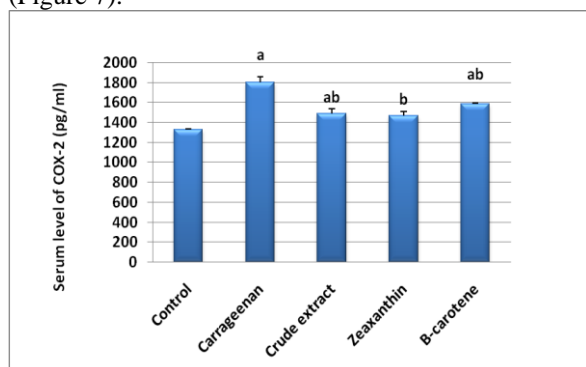


**Figure 6: Effects of carotenoid enrich fractions of *Dunaliella salina* on serum level of TNF- $\alpha$  and IL-6**

Data were expressed as mean  $\pm$  SE. Statistical analysis was carried out by one-way ANOVA followed by Tukey's multiple comparisons test. <sup>a</sup> Significantly different from normal control at  $P < 0.05$ . <sup>b</sup> Significantly different from carrageenan control at  $P < 0.05$ . <sup>c</sup> Significantly different from crude extract at  $P < 0.05$ . <sup>d</sup> Significantly different from zeaxanthin at  $P < 0.05$ .

#### Effects of carotenoids enrich fractions of *D. salina* microalgae on COX-2 and PGE2 serum levels

COX-2 and PGE2 elevated by 36% and 87% in carrageenan control group as compared with normal control, while Administration of crude extract, Zeaxanthin and  $\beta$ -carotene showed a significant decrease of COX-2 concentration by 17%, 19%, and 12%, respectively, and PGE2 release by 47%, 49% and 21%, respectively, as compared with carrageenan control group. In addition administration of zeaxanthin only returned COX-2 serum level to its normal value while crude extract and zeaxanthin administration normalized PGE2 (Figure 7).



**Figure 7: Effects of carotenoid enrich fractions of *Dunaliella salina* on serum level of COX-2 and PGE2**

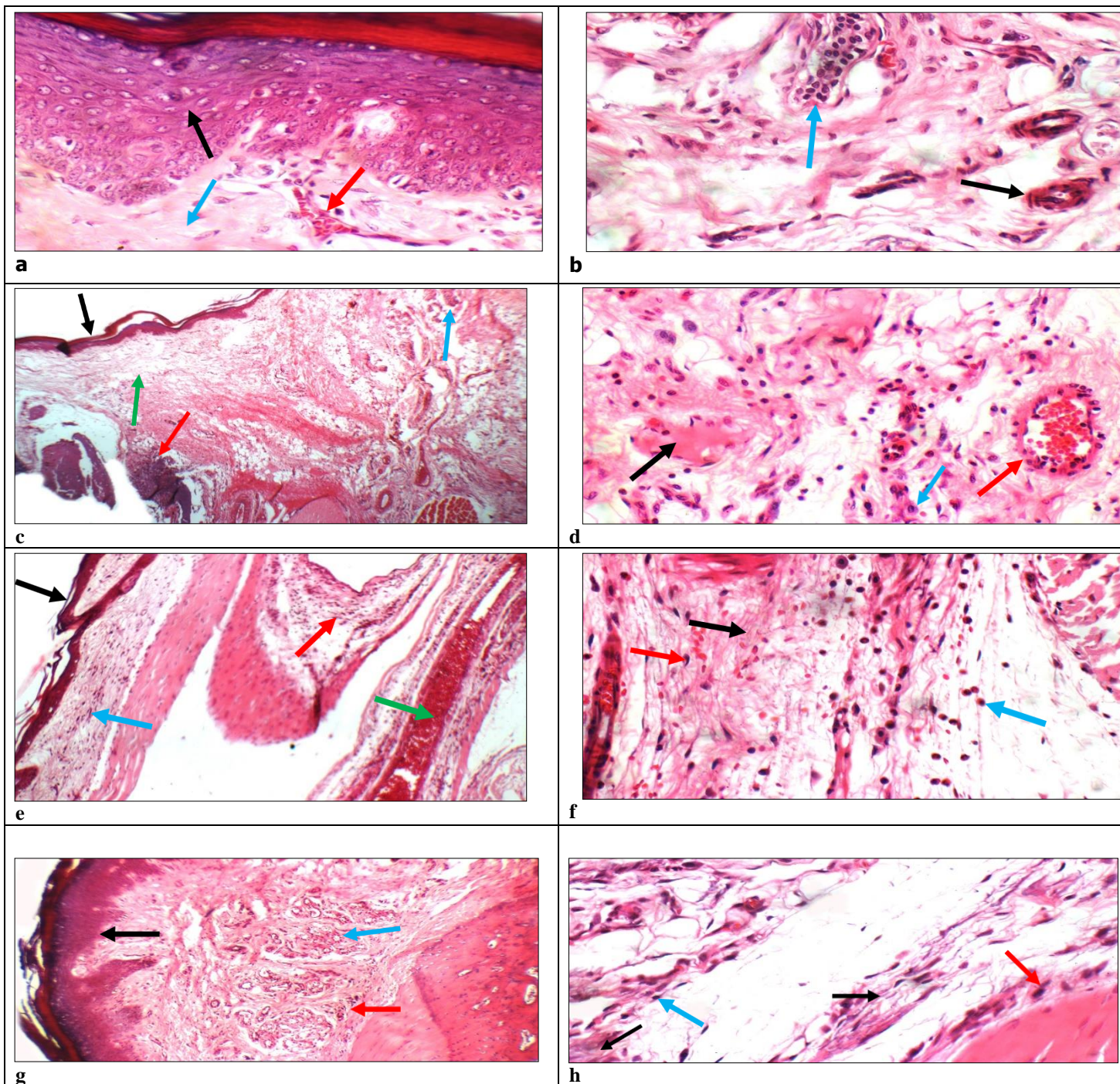
Data were expressed as mean  $\pm$  SE. Statistical analysis was carried out by one-way ANOVA followed by Tukey's multiple comparisons test. <sup>a</sup> Significantly different from normal control at  $P < 0.05$ . <sup>b</sup> Significantly different from carrageenan control at  $P < 0.05$ . <sup>c</sup> Significantly different from crude extract at  $P < 0.05$ . <sup>d</sup> Significantly different from zeaxanthin at  $P < 0.05$ .

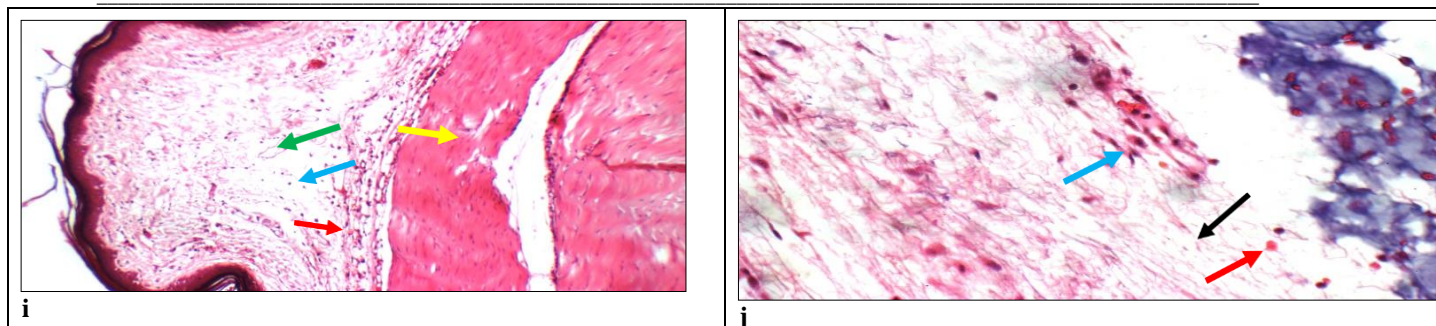
#### Histopathological results

Normal control group showed average keratinized epidermis with average keratinocytes (black arrow), average collagen (blue arrow), and average superficial blood vessels (red arrow) (H& X 200). Normal control showed deep dermis with average deep blood vessels (black arrow), and average sweat glands (blue arrow) (H& X 400). Carrageenan group showed thin keratinized epidermis (black arrow), dermis with few pilo-sebaceous units (blue arrow), marked oedema (green arrow), and marked inflammatory infiltrate extending to underlying cartilage (red arrow) (H& X 200). Carrageenan group showed deep dermis with marked oedema (black arrow), marked inflammatory infiltrate with excess neutrophils (blue arrow), and mildly congested deep blood vessels (red arrow) (H& X 400). Crude extract group showed thin keratinized epidermis (black arrow), upper dermis with mild inflammatory infiltrate (blue arrow), and deep dermis with markedly dilated congested deep blood vessels (green arrow), and moderate inflammatory infiltrate (red arrow) (H& X 200). Crude extract group showed deep dermis with marked oedema (black arrow), moderate inflammatory infiltrate (blue arrow), and extravasated red cells (red arrow) (H& X 400). Zeaxanthin group showed average keratinized epidermis (black arrow), upper dermis with average pilo-sebaceous units (blue arrow), and mild inflammatory infiltrate in deep dermis (red arrow) (H& X 200). Zeaxanthin group showed deep dermis with mild oedema (black arrow), and mild inflammatory infiltrate (blue arrow) extending to underlying muscles (red arrow) (H& X 400).  $\beta$ -carotene group showed average keratinized epidermis (black arrow), upper dermis with mild oedema (blue arrow) and average blood vessels (green arrow), deep dermis with mild inflammatory

infiltrate (red arrow), and free muscles (yellow arrow) (H& X 200).  $\beta$ -carotene group showed deep dermis with marked oedema (black arrow), moderate inflammatory infiltrate (blue arrow), and

extravasated red cells (red arrow) (H& X 400) (Figure 8).





**Figure 8: Effects of carotenoid enrich fractions of *Dunaliella salina* on skin histopathology**

(a): Control showing average keratinized epidermis with average keratinocytes (black arrow), average collagen (blue arrow), and average superficial blood vessels (red arrow) (H& X 200). (b): Control showing deep dermis with average deep blood vessels (black arrow), and average sweat glands (blue arrow) (H& X 400). (c): Carrageenan group showing thin keratinized epidermis (black arrow), dermis with few pilo-sebaceous units (blue arrow), marked edema (green arrow), and marked inflammatory infiltrate extending to underlying cartilage (red arrow) (H& X 200). (d): Carrageenan group showing deep dermis with marked edema (black arrow), marked inflammatory infiltrate with excess neutrophils (blue arrow), and mildly congested deep blood vessels (red arrow) (H& X 400). (e): Crude extract group showing thin keratinized epidermis (black arrow), upper dermis with mild inflammatory infiltrate (blue arrow), and deep dermis with markedly dilated congested deep blood vessels (green arrow), and moderate inflammatory infiltrate (red arrow) (H& X 200). (f): Crude extract group showing deep dermis with marked edema (black arrow), moderate inflammatory infiltrate (blue arrow), and extravasated red cells (red arrow) (H& X 400). (g): Zeaxanthin group showing average keratinized epidermis (black arrow), upper dermis with average pilo-sebaceous units (blue arrow), and mild inflammatory infiltrate in deep dermis (red arrow) (H& X 200). (i): Zeaxanthin group showing deep dermis with mild edema (black arrow), and mild inflammatory infiltrate (blue arrow) extending to underlying muscles (red arrow) (H& X 400). (j):  $\beta$ -carotene group showing average keratinized epidermis (black arrow), upper dermis with mild edema (blue arrow) and average blood vessels (green arrow), deep dermis with mild inflammatory infiltrate (red arrow), and free muscles (yellow arrow) (H& X 200). (h):  $\beta$ -carotene group another view showing deep dermis with marked edema (black arrow), moderate inflammatory infiltrate (blue arrow), and extravasated red cells (red arrow) (H& X 400).

#### 4. Discussion

In the present study, we analyze *D. salina* microalgae carotenoid enrich fractions using HPLC and evaluate the anti-inflammatory activity of *D. salina* microalgae and its carotenoids enrich fractions and the mechanism by which they exert their effects. The extraction by hexane/ethyl acetate (1:1, V/V) in this study showed a positive effect on the recovery of  $\beta$ -carotene from *D. salina* as compared with the previous result of El-Baz et al.<sup>26</sup>, that demonstrated low recovery of  $\beta$ -carotene (0.159 mg/g algal powder) from *D. salina* extracted by ethanol/water (7:3, v/v). Moreover, under the present study condition the content of zeaxanthin (0.350 mg/g algal powder) of *D. salina* is higher than zeaxanthin content (0.2 mg/g dry weight) of Wild-type *D. salina* Teod., while it is lower than zeaxanthin content (6 mg/g dry weight) of new mutant (zea1) of *D. salina* developed by Jin et al.<sup>27</sup>. The  $\beta$ -carotene and zeaxanthin content of *D. salina* extracted with hexane/ethyl acetate in this study is higher than the  $\beta$ -carotene (5.07 mg/g crud extract) and zeaxanthin (11.32 mg/g crude extract) content of *Chlorella saccharophila* extracted with acetone<sup>28</sup>. Carrageenan is a suitable experimental animal model to determine the antioedematous and anti-inflammatory effect of diverse bioactive compounds such as plant extracts and essential oils<sup>29, 30</sup>. In this model of inflammation, Carrageenan provoked an elevation in the paw thickness of rat. Injection of carrageenan induced a progressive inflammation and oedema into the hind paw<sup>31</sup>. This inflammation is a

biphasic response; the first one is mediated via serotonin and kinins release and the second phase is related to prostaglandin release<sup>29, 32</sup>.

Microalgae exhibited a wonderful defense strategy, lived in different physico-chemical conditions and evolved with natural bio-products which have functional properties in the human body and alternatives to chemical compounds. *D. salina* microalgae and its carotenoids rich fractions have a consistent anti-inflammatory property via decreasing the paw thickness of rat. *D. salina* is safe as previously reported<sup>33</sup>. Some researchers have proposed the anti-fibrotic and anti-inflammatory activity of *D. salina* microalgae against liver fibrosis<sup>34, 35</sup>. Besides its anti-inflammatory effect, it has antioxidant activity that involved in potential health applications which scavenges free radicals and oxidation that produced pathological conditions protecting against the cell-damaging activities such as diabetic neuropathy<sup>36</sup>. In current study, *D. salina* microalgae carotenoids enrich fractions decreased paw oedema thickness. In addition, the serotonergic system is likely to be involved in the modulating action of *D. salina* microalgae carotenoids enrich fractions on peripheral inflammation induced by carrageenan.

Among the over 400 carotenoids, only few are commercially used: astaxanthin,  $\beta$ -carotene, lutein, zeaxanthin, lycopene and bixin<sup>37</sup>. The most important uses of them are natural food colorants (e.g., orange juice) and additives for animal feed



(poultry, fish). Carotenoids used also in cosmetics. Carotenoids nutritional and therapeutic relevance is owing to their conversion into vitamin A<sup>38</sup> and they having systemic anti-inflammatory properties<sup>39</sup>. In the current study, carrageenan-induced stimulated TNF- $\alpha$  release, this, in turn, increased IL-6 secretion. The promotion of the secretion of inflammatory cytokine is involved in the inflammatory response induced by carrageenan<sup>40</sup>. Crude extract, zeaxanthin and  $\beta$ -carotene suppressed TNF- $\alpha$  and IL-6 release.  $\beta$ -carotene has antiinflammatory effect in a recent study of El-Baz et al.<sup>26</sup> on thioacetamide (TAA)-induced fibrosis model in rats which declared that consumption of *D. salina* powder tablets rich in  $\beta$ -carotene improved the liver fibrosis injures in rats through the decrease of inflammatory mediators; TNF- $\alpha$ , transforming growth factor-beta, alpha- and the reduction of hepatic contents of collagen-1 and smooth muscle actin with the increase of metalloproteinase 9. Zeaxanthin, also, displays protecting properties against acetic acid-induced colitis in rats through reduction of TNF- $\alpha$ , interferon-gamma, nuclear transcription factor kappa B levels, interleukin-6, and interleukin-1 beta along with inhibition of cyclooxygenase-2 protein and nitric oxide synthase expression<sup>41</sup>. Moreover, it exerts anti-inflammatory effect against carrageenan, formalin, and dextran induced paw oedema of mice. It also presented anti-inflammatory influence against LPS-induced inflammation in macrophages<sup>42</sup>. The cyclooxygenase has a vital role in the inflammatory process of carrageenan and is responsible for the production of prostaglandins<sup>29</sup>. cyclooxygenase inhibition is more effective in suppressing inflammation-induced by carrageenan<sup>43</sup>. Our results indicated that carrageenan induced dysregulation of proteins expression of COX-2 and PGE2, while administration with crude extract, zeaxanthin and  $\beta$ -carotene showed a significant decline in the activities of COX-2 and PGE2 compared to carrageenan-treated group. The carrageenan stimulated of extracellular signal-regulated kinase 1/2 (ERK1/2) and c-Jun N-terminal kinase (JNK) proteins phosphorylation induced the release of TNF- $\alpha$ <sup>18</sup>, which, in turn, stimulated COX-2 and PGE2 secretion<sup>44</sup>.

### Conclusion

This study suggests that the use of valuable enrich fractions from *D. salina* microalgae have a significant anti-inflammatory effect against carrageenan-induced paw oedema in rat via down regulation of TNF- $\alpha$ , IL-6, and COX-2/PGE2 pathway. *D. salina* microalgae and its carotenoids enrich fractions have commercial interest. So, clinical Studies are needed for further identifying the activities of potential bioproducts in the diseases treatment or prevention.

### Conflicts of Interest

The authors declare that they have no conflicts of interest.

### References

1. Patil, K. R.; Mahajan, U. B.; Unger, B. S.; Goyal, S. N.; Belemkar, S.; Surana, S. J.; Ojha, S.; Patil, C. R. Animal models of inflammation for screening of anti-inflammatory drugs: Implications for the discovery and development of phytopharmaceuticals. *International journal of molecular sciences* **2019**, *20*, 4367.
2. Abd-Allah, A. A. M.; El-Deen, N. A. M. N.; Mohamed, W. A. M.; Naguib, F. M. Mast cells and pro-inflammatory cytokines roles in assessment of grape seeds extract anti-inflammatory activity in rat model of carrageenan-induced paw edema. *Iranian journal of basic medical sciences* **2018**, *21*, 97.
3. Abbate, G. M.; Sacerdote, P.; Amodeo, G.; Mangano, A.; Levrini, L. Experimentally Induced Pulpal Lesion and Substance P Expression: Effect of Ketoprofen—A Preliminary Study. *International Journal of Dentistry* **2016**, 2016.
4. Buchner, J.; Li, J. Structure, function and regulation of the hsp90 machinery. *Biomedical journal* **2013**, *36*, 106.
5. Al-Wajeeh, N. S.; Hajerezaie, M.; Noor, S. M.; Halabi, M. F.; Al-Henhena, N.; Azizan, A. H. S.; Kamran, S.; Hassandarvish, P.; Shwter, A. N.; Ali, H. M. The gastro protective effects of Cibotium barometz hair on ethanol-induced gastric ulcer in Sprague-Dawley rats. *BMC veterinary research* **2016**, *13*, 1-12.
6. Böhm, V.; Puspitasari-Nienaber, N. L.; Ferruzzi, M. G.; Schwartz, S. J. Trolox equivalent antioxidant capacity of different geometrical isomers of  $\alpha$ -carotene,  $\beta$ -carotene, lycopene, and zeaxanthin. *Journal of agricultural and food chemistry* **2002**, *50*, 221-226.
7. Rodriguez-Concepcion, M.; Avalos, J.; Bonet, M. L.; Boronat, A.; Gomez-Gomez, L.; Hornero-Mendez, D.; Limon, M. C.; Meléndez-Martínez, A. J.; Olmedilla-Alonso, B.; Palou, A. A global perspective on carotenoids: Metabolism, biotechnology, and benefits for nutrition and health. *Progress in lipid research* **2018**, *70*, 62-93.
8. El-Baz, F. K.; Aly, H. F.; Abd-Alla, H. I. The ameliorating effect of carotenoid rich fraction extracted from Dunaliella salina microalga against inflammation-associated cardiac dysfunction in obese rats. *Toxicology reports* **2020**, *7*, 118-124.

9. Seckbach, J. *Enigmatic microorganisms and life in extreme environments*. Springer Science & Business Media: 2013; Vol. 1.
10. El-Baz, F. K.; Hussein, R. A.; Saleh, D. O.; Abdel-Jaleel, G. A. R. Zeaxanthin Isolated from *Dunaliella salina* Microalgae Ameliorates Age Associated Cardiac Dysfunction in Rats through Stimulation of Retinoid Receptors. *Marine drugs* **2019**, 17.
11. Christen, W. G.; Gaziano, J. M.; Hennekens, C. H.; PHYSICIANS, F. T. S. C. O.; STUDY II, H. Design of Physicians' Health Study II—a randomized trial of beta-carotene, vitamins E and C, and multivitamins, in prevention of cancer, cardiovascular disease, and eye disease, and review of results of completed trials. *Annals of epidemiology* **2000**, 10, 125-134.
12. Werman, M. J.; Ben-Amotz, A.; Mokady, S. Availability and antiperoxidative effects of  $\beta$ -carotene from *Dunaliella bardawil* in alcohol-drinking rats. *The Journal of nutritional biochemistry* **1999**, 10, 449-454.
13. Mozaffarieh, M.; Sacu, S.; Wedrich, A. The role of the carotenoids, lutein and zeaxanthin, in protecting against age-related macular degeneration: a review based on controversial evidence. *Nutrition journal* **2003**, 2, 1-8.
14. Grudzinski, W.; Piet, M.; Luchowski, R.; Reszczynska, E.; Welc, R.; Paduch, R.; Gruszecki, W. I. Different molecular organization of two carotenoids, lutein and zeaxanthin, in human colon epithelial cells and colon adenocarcinoma cells. *Spectrochimica Acta Part A: Molecular and Biomolecular Spectroscopy* **2018**, 188, 57-63.
15. Ribaya-Mercado, J. D.; Blumberg, J. B. Lutein and zeaxanthin and their potential roles in disease prevention. *Journal of the American College of Nutrition* **2004**, 23, 567S-587S.
16. Stein, J. R.; Hellebust, J. A.; Craigie, J. *Handbook of phycological methods: culture methods and growth measurements*. Cambridge University Press: 1973.
17. Sarada, R.; Vidhyavathi, R.; Usha, D.; Ravishankar, G. An efficient method for extraction of astaxanthin from green alga *Haematococcus pluvialis*. *Journal of agricultural and food chemistry* **2006**, 54, 7585-7588.
18. Abd El-Karim, S. S.; Mohamed, H. S.; Abdelhameed, M. F.; Amr, A. E.-G. E.; Almehezia, A. A.; Nossier, E. S. Design, synthesis and molecular docking of new pyrazole-thiazolidinones as potent anti-inflammatory and analgesic agents with TNF- $\alpha$  inhibitory activity. *Bioorganic Chemistry* **2021**, 111, 104827.
19. Winter, C. A.; Risley, E. A.; Nuss, G. W. Carrageenin-induced edema in hind paw of the rat as an assay for antiinflammatory drugs. *Proceedings of the society for experimental biology and medicine* **1962**, 111, 544-547.
20. Obukowicz, M. G.; Welsch, D. J.; Salsgiver, W. J.; Martin-Berger, C. L.; Chinn, K. S.; Duffin, K. L.; Raz, A.; Needleman, P. Novel, selective  $\Delta 6$  or  $\Delta 5$  fatty acid desaturase inhibitors as antiinflammatory agents in mice. *Journal of Pharmacology and Experimental Therapeutics* **1998**, 287, 157-166.
21. El Kady, W. M.; Salama, A. A.; Desoukey, S. Y.; Hagag, E. G.; El-Shenawy, S. M.; El-Shanawany, M. Comparative DNA profiling, botanical identification and biological evaluation of *Gazania longiscapa* DC and *Gazania rigens* L. *Bulletin of Faculty of Pharmacy, Cairo University* **2015**, 53, 129-145.
22. El-Baz, F. K.; Salama, A. A. A.; Hussein, R. A. *Dunaliella salina* microalgae oppose thioacetamide-induced hepatic fibrosis in rats. *Toxicology reports* **2020**, 7, 36-45.
23. Csepanyi, E.; Czompa, A.; Haines, D.; Lekli, I.; Bakondi, E.; Balla, G.; Tosaki, A.; Bak, I. Cardiovascular effects of low versus high-dose beta-carotene in a rat model. *Pharmacological research* **2015**, 100, 148-156.
24. Salama, A.; Hegazy, R.; Hassan, A. Intranasal Chromium Induces Acute Brain and Lung Injuries in Rats: Assessment of Different Potential Hazardous Effects of Environmental and Occupational Exposure to Chromium and Introduction of a Novel Pharmacological and Toxicological Animal Model. *PloS one* **2016**, 11, e0168688.
25. Basha, M.; Salama, A.; Noshi, S. H. Soluplus® based solid dispersion as fast disintegrating tablets: a combined experimental approach for enhancing the dissolution and antiulcer efficacy of famotidine. *Drug development and industrial pharmacy* **2020**, 46, 253-263.
26. El-Baz, F. K.; Ali, S. I.; Basha, M.; Kassem, A. A.; Shamma, R. N.; Elgohary, R.; Salama, A. Design and evaluation of bioenhanced oral tablets of *Dunaliella salina* microalgae for treatment of liver fibrosis. *Journal of Drug Delivery Science and Technology* **2020**, 101845.
27. Jin, E.; Feth, B.; Melis, A. A mutant of the green alga *Dunaliella salina* constitutively accumulates zeaxanthin under all growth conditions. *Biotechnology and bioengineering* **2003**, 81, 115-124.
28. Singh, D.; Puri, M.; Wilkens, S.; Mathur, A. S.; Tuli, D. K.; Barrow, C. J. Characterization of a new zeaxanthin producing strain of *Chlorella*

- saccharophila isolated from New Zealand marine waters. *Bioresource technology* **2013**, 143, 308-314.
29. Abdallah, H. M.; Ammar, N. M.; Abdelhameed, M. F.; Gendy, A. E.-N. G. E.; Ragab, T. I.; Abd-ElGawad, A. M.; Farag, M. A.; Alwahibi, M. S.; Elshamy, A. I. Protective mechanism of Acacia saligna butanol extract and its nano-formulations against ulcerative colitis in rats as revealed via biochemical and metabolomic assays. *Biology* **2020**, 9, 195.
  30. Sforzin, J.; Amaral, J.; Fernandes Jr, A.; Sousa, J.; Bastos, J. Lemongrass effects on IL-1 $\beta$  and IL-6 production by macrophages. *Natural product research* **2009**, 23, 1151-1159.
  31. Abd El-Alim, S. H.; Kassem, A. A.; Basha, M.; Salama, A. Comparative study of liposomes, ethosomes and transfersomes as carriers for enhancing the transdermal delivery of diflunisal: in vitro and in vivo evaluation. *International journal of pharmaceutics* **2019**, 563, 293-303.
  32. Z Shaban, N.; M Sadek, O.; A Andraws, E. The anti-inflammatory effect of ethanolic ginger extract against carrageenan-induced rat paw edema. *Biochemistry Letters* **2019**, 15, 114-125.
  33. El-Baz, F. K.; Aly, H. F.; Salama, A. A. A. Toxicity assessment of the green Dunaliella salina microalgae. *Toxicology reports* **2019**, 6, 850-861.
  34. Anbuechezian, R.; Karuppiah, V.; Li, Z. Prospect of marine algae for production of industrially important chemicals. In *Algal biorefinery: An integrated approach*, Springer: 2015; pp 195-217.
  35. El-Baz, F. K.; Salama, A.; Salama, R. A. A. Therapeutic Effect of Dunaliella salina Microalgae on Thioacetamide- (TAA-) Induced Hepatic Liver Fibrosis in Rats: Role of TGF- $\beta$  and MMP9. *BioMed research international* **2019**, Article ID 7028314, 9 page.
  36. El-Baz, F. K.; Salama, A.; Salama, R. A. A. Dunaliella salina Attenuates Diabetic Neuropathy Induced by STZ in Rats: Involvement of Thioredoxin. *BioMed research international* **2020**, 2020, 1295492.
  37. Suganya, T.; Varman, M.; Masjuki, H.; Renganathan, S. Macroalgae and microalgae as a potential source for commercial applications along with biofuels production: a biorefinery approach. *Renewable and Sustainable Energy Reviews* **2016**, 55, 909-941.
  38. Toti, E.; Chen, C.-Y. O.; Palmery, M.; Villaño Valencia, D.; Peluso, I. Non-provitamin A and provitamin A carotenoids as immunomodulators: recommended dietary allowance, therapeutic index, or personalized nutrition? *Oxidative medicine and cellular longevity* **2018**, 2018.
  39. Murillo, A. G.; Hu, S.; Fernandez, M. L. Zeaxanthin: metabolism, properties, and antioxidant protection of eyes, heart, liver, and skin. *Antioxidants* **2019**, 8, 390.
  40. Amdekar, S.; Roy, P.; Singh, V.; Kumar, A.; Singh, R.; Sharma, P. Anti-inflammatory activity of lactobacillus on carrageenan-induced paw edema in male wistar rats. *International journal of inflammation* **2012**, 2012.
  41. El-Akabawy, G.; El-Sherif, N. M. Zeaxanthin exerts protective effects on acetic acid-induced colitis in rats via modulation of pro-inflammatory cytokines and oxidative stress. *Biomedicine & Pharmacotherapy* **2019**, 111, 841-851.
  42. Firdous, A.; Kuttan, G.; Kuttan, R. Anti-inflammatory potential of carotenoid meso-zeaxanthin and its mode of action. *Pharmaceutical biology* **2015**, 53, 961-967.
  43. Shrivastava, S. K.; Srivastava, P.; Bandresh, R.; Tripathi, P. N.; Tripathi, A. Design, synthesis, and biological evaluation of some novel indolizine derivatives as dual cyclooxygenase and lipoxygenase inhibitor for anti-inflammatory activity. *Bioorganic & medicinal chemistry* **2017**, 25, 4424-4432.
  44. Ou, Z.; Zhao, J.; Zhu, L.; Huang, L.; Ma, Y.; Ma, C.; Luo, C.; Zhu, Z.; Yuan, Z.; Wu, J. Anti-inflammatory effect and potential mechanism of betulinic acid on  $\lambda$ -carrageenan-induced paw edema in mice. *Biomedicine & Pharmacotherapy* **2019**, 118, 109347.