



## Toxicological Aspects of Fluoroquinolones Administration: A Literature Review

Ameera Kamal Khaleel,<sup>1</sup> Ramizu Bin Shaari<sup>2</sup>, Mohamad Arif Awang Nawi<sup>3</sup>,  
Ali Mihsen Hussein Al-Yassiri<sup>4</sup>.

<sup>1,2,3</sup> Health Campus, Universiti Sains Malaysia, Kubang Kerian, 16150 Kota Bharu,  
Kelantan, Malaysia.

<sup>4</sup> Hilla University College, Babylon, Iraq



CrossMark

### Abstract

Fluoroquinolone associated toxicity after long-term fluoroquinolone antibiotic therapy appears as a significant medical and social problem. The objective of this review was mainly to identify, collect and evaluate the available evidence regarding the toxicological aspects of fluoroquinolone with focus on the causes of fluoroquinolone chondrotoxicity in juvenile animals. The present review was conducted using the PubMed/Medline databases. English language publications, original studies and reviews were included. All works about the fluoroquinolones regarding human, in vitro, and animal studies published in the medical and dental literature between 1985 and 2021 were reviewed. The existing data studies demonstrate that fluoroquinolone administration can cause different side effects, and the fluoroquinolone chondrotoxicity in juvenile animals is one of them. The cause could be due to binding of fluoroquinolone with the divalent cations such as Mg<sup>2+</sup> and this can induce a deficiency of the functionally available magnesium, increase level of tissue apoptotic markers like activated caspase-3, reactive oxygen species (ROS) overproduction, mitochondrial damage, enhanced the expression of matrix metalloproteinases, with chondrocytes loss and decrease in the formation of the cartilage extracellular matrix. Depending on these toxicological findings in animal studies during the postnatal growth, fluoroquinolones are contraindicated during pregnancy, lactation, and in children.

**Keywords:** Fluoroquinolones, Antibiotics, Chondrotoxicity, Caspase, Mg<sup>2+</sup>.

### 1. Introduction

Nalidixic acid, the quinolone, was a byproduct of the synthesis of chloroquine in 1960 “[1]”. The spectrum of its activity against the gram-negative bacteria of this non-fluorinated substance is very narrow. Later in the 1980 fluorinated derivatives were synthesized “[2]”. The fluorinated analogues of the nalidixic acid, a 1,8-naphthyridine with a 4-quinolone nucleus are important compounds of fluoroquinolones (Figure -1). The C-6 carbon of the basic ring structure is the site of fluorination [as comes in 1 and 2]. They have a broad antibacterial activity that includes both gram negative and positive aerobic with the anaerobic species “[3, 4]”.

The active substances of fluoroquinolones are ciprofloxacin, enoxacin, cinoxacin, levofloxacin, flumequin, moxifloxacin, lomefloxacin, ofloxacin, norfloxacin, pefloxacin, prulifloxacin, rufloxacin and pipemidic acid. They are prescribed widely and are important for the treatment of a serious bacterial infection “as mentioned in [5]”. Ciprofloxacin, which

is the most widely and successfully used fluoroquinolones, was marketed in 1986, and since that time, the fluoroquinolones uses for the treatment of different infectious diseases have become so widely increased “as comes in [6]”. The fluoroquinolones classification on the basis of their pharmacokinetic and the characteristic features is seen in Table-1 “[7, 8, 9, 10]”.

Fluoroquinolones act by inhibition of the DNA gyrase bacterial enzyme, which nicks the double-stranded DNA, and produces negative super coils. After that it cause resealing to the nicked end. This action cause prevention in the positive supercoiling of DNA strands when they are separate in order to facilitate replication and transcription. This inhibitory action can interrupt the DNA replication and transcription, and preventing cell division in different bacterial cells [as comes in 5, 11, 12].

\*Corresponding author e-mail: [ameerakkh2021@gmail.com](mailto:ameerakkh2021@gmail.com); (Ameera Kamal Khaleel).

Receive Date: 03 October 2021, Revise Date: 04 October 2021, Accept Date: 06 November 2021

DOI: [10.21608/ejchem.2021.99250.4617](https://doi.org/10.21608/ejchem.2021.99250.4617)

©2020 National Information and Documentation Center (NIDOC)

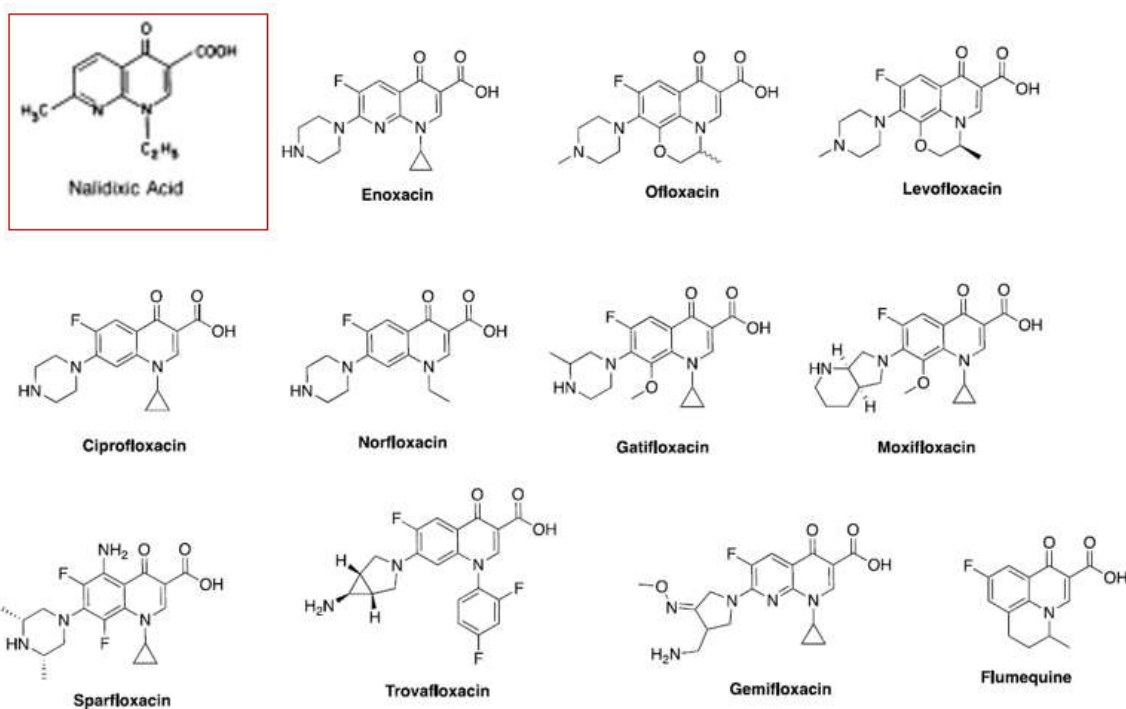


Figure1: Structure of nalidixic acid and some selected fluoroquinolone.

Table 1: Fluoroquinolones classification

Type of generation	Type of drug	Characteristic features
<b>First</b>	Nalidixic acid Pipemidic acid Oxolinic acid	Activity against some gram-negative bacteria. High protein binding about 90%. Associated with little half-life. Bacteria can develop a rapid resistance.
<b>Second</b>	Ciprofloxacin Norfloxacin Enoxacin Ofloxacin Lomefloxacin	Activity against gram positive and negative bacteria. Protein binding about 50% with improved tissue distribution. Associated with longer half-life.
<b>Third</b>	Temafloxacin Sparafloxacin Grepafloxacin	Active against the gram positive and the gram-negative bacteria.
<b>Fourth</b>	Clinafloxacin Gatifloxacin Trovafloxacin Moxifloxacin	Active against anaerobes and atypical bacteria. Extended activity against both strains of bacteria.

## 2. Fluoroquinolone general information

### 2.1. Antimicrobial properties

Fluoroquinolones have a good and a wide spectrum activity against the gram - positive and gram-negative bacteria, and this activity against the both types was seen associated with some types of them "[7]". Excellent activity was seen against the gram-negative type such as the members of the family of Enterobacteriaceae, *Haemophilus influenzae*, *Neisseria gonorrhoeae*, *Pseudomonas aeruginosa*, *Moraxellacatarrhalis*, and *Neisseria meningitides*.

Most of gram-negative bacteria are responsible for the urinary tract infections showed high sensitivity to fluoroquinolones [as comes in 13].

Ofloxacin and ciprofloxacin were showed excellent activity against the *Staphylococcus aureus*, like the penicillin and methicillin sensitive strains. Several other bacteria are inhibited by the fluoroquinolones use like species of *Chlamydia*, *Legionella*, *Mycoplasma*, *Mycobacterium*, and *Brucella*. Levofloxacin, grepafloxacin, sparfloxacin, and trovafloxacin shows a significant activity against the *Mycoplasma pneumoniae*, *Chlamydia pneumoniae*, and *Legionella pneumophila*. Ofloxacin and ciprofloxacin shows less activity against the *Mycobacterium tuberculosis* [14]. Trovafloxacin was seen active against *B. fragilis*, *Peptostreptococci*, *Clostridium perfringens*, and *C. difficile*. The fluoroquinolones ability to decrease SARS-CoV-2 replication in vitro was seen very limited "as comes in [15]".

**2.2. Development of microbial resistance:** The wide use of the fluoroquinolones causes increasing concern for development of microbial resistance. Several mechanisms for development of resistance were seen ["as mentioned in 16 and 17"]:

1. Development of genes mutations which encode bacterial topoisomerase II and IV, this result in altered binding affinity of the drug and reduction in its action.
2. Reduction in intracellular drug exposure due to development of bacterial efflux transporters.
3. A plasmid which carries the gene *qnrA* has been discovered which leads to the inherent mechanism of resistance.

### 2.3. Drug interaction

Absorption of fluoroquinolones by oral administration is drastically decreased by using antacid containing aluminum, magnesium, and sucralfate. The new compounds interact with multivalent cation containing compounds. Decrease in the oral bioavailability can be by ranitidine. This indicates that the oral absorption of some types of fluoroquinolones can be affected by the gastric pH which affects the dissolution [8]. Interaction between fluoroquinolones and methylxanthines like caffeine was also found, which can increase the serum theophylline to a great extent [18].

Buck (1998) study found that the antineoplastic drugs serum concentration was seen decrease because of the interaction with ciprofloxacin [19]. Interaction with probenecid, cimetidine, and azlocillin causing decrease in clearance of these drugs with increased in serum level of ciprofloxacin "as comes in [19,20]".

The drugs, like citrates and sodium bicarbonate which causes the urine to be alkaline, cause reduction in the norfloxacin solubility and hence the development of crystalluria [20].

### 2.4. Pharmacokinetic

The pharmacokinetic profile of newer analogs of fluoroquinolones shows a long serum half-life, greater maximum plasma concentration, more extensive coverage above the minimum inhibitory concentration and permits one daily dose [as comes in 21]. Fluoroquinolones when are used with other antibiotic classes, like aminoglycosides and beta-lactams, they are not predictably synergistic [15]. Following oral administration, the complete absorption of fluoroquinolones is not always achieved [8]. The peak serum concentrations of most types of the fluoroquinolones are achieved in one to three hours after oral administration [22].

After oral administration, most fluoroquinolones show little binding to plasma proteins, and for this reason, the distribution of fluoroquinolones to tissues is superior to most other antibiotics [as comes in 23], and a high drug level is found in prostate gland, kidney, lung, and liver. Fluoroquinolones are distributed rapidly in tissues [24]. Only in the brain, the P-glycoprotein can play important role in this condition [25].

Most of fluoroquinolones are eliminated by the kidney by the glomerular filtration and tubular secretion, so the dosage adjustment is important in patients suffered from renal failure. The liver is the secondary route of excretion. Peritoneal dialysis and hemodialysis are poor way for clearing fluoroquinolones [22].

### 2.5. Therapeutic uses

The fluoroquinolones are used widely, and this use is constantly growing. It was used widely for the treatment of urinary tract infections and prostatitis [26], gastrointestinal infections [27], typhoid fever [28], rectal and/or pharyngeal gonococcal infections [29], sexually transmitted disease [30], pneumonia [31], osteomyelitis [13], and mycobacterial diseases, especially tuberculosis and leprosy [32].

### 2.6. Adverse effects

The most common side effects are hypersensitivity [33], tendon/articular toxicity "as comes in [34,35,36,37,38]", numbness, seizures, insomnia, restlessness, convulsions, psychosis [as comes in 39,40,41], nausea, vomiting, diarrhea, headache, and insomnia [42], cardiotoxicity [43], hepatic toxicity [44,45], photosensitivity [16],

development of type 2 diabetes mellitus “[46]”, and rarely renal failure “[47]”. For this reason, the fluoroquinolone use was decreased with the largest decreases was found in inpatient, especially the ciprofloxacin users “[48]”.

### 3. Fluoroquinolone chondrotoxicity

During pregnancy, fluoroquinolones are contraindicated, as well as in lactation period, children and adolescents, depending on the toxicological results in animals' studies during the postnatal growth “[49]”. The chondrotoxicity in some animals was induced by some quinolones by a dose of 10 mg/kg b.w. But to induce joint arthropathy in rats a higher dose is needed “[50]”.

#### 3.1 Clinical features

The cartilage lesion was found limited to juvenile animals only, but in case with pefloxacin treatment, these changes have been found in adult and juvenile dogs, but after a prolonged administration of the drug “[51]”. Clinically, the most common features are joint pain and swelling, and an inability to walk seen was seen in severe cases “[52]”. Bilateral solitary or multiple protruding blisters are seen associated with the articular cartilage of the epiphyses of bones. Some articular cartilages were seen associated with erosion of the upper surface. The articular cartilage lesions show a tendency toward healing even in case of a continued administration of the fluoroquinolone, but this healing is incomplete even after a long recovery period “[53]”.

#### 3.2. Magnetic resonance image

Magnetic resonance image of the joints showed a thickened articular cartilage with surface irregularities. Due to synovial effusion, separation of the opposing articular surfaces was also seen “[54]”.

#### 3.3. Histological features

The histological changes which are usually detected are: Degeneration and necrosis of the chondrocyte's cells, matrix degeneration with marked decrease in stainability with Safranin O, cavitation or cleft formation in the center of edematous articular cartilage which may be detached and lead to the formation of erosions, loss of proteoglycans, alters collagen fibrillogenesis “as comes in [55,56,57,58]”.

#### 3.4. Causes

The possible explanation of fluoroquinolone chondrotoxicity could be due to:

##### 3.4.1. Chelating properties of fluoroquinolones against the metal ions

Fluoroquinolones have two sites for formation of metal chelate; the carboxyl and the carbonyl groups which represent the most important coordinate mode in the chelation. They can bind the divalent or the trivalent cations such as  $Mg^{2+}$ ,  $Ca^{2+}$ ,  $Cu^{2+}$ ,  $Zn^{2+}$ ,  $Fe^{2+}$ ,  $Co^{2+}$ ,  $Al^{3+}$  and  $Fe^{3+}$  “[59]”. A deficiency of functionally available magnesium was induced because of the formation of a chelate complexes with divalent cations like  $Mg^{2+}$  “[60]”. It was found that the activity of integrin receptors of the  $\beta 1$  subfamily which can activate the chondrocyte interaction with fibronectin, type I and type II collagen and also important in cell-matrix interactions in the cartilage of the joints strongly depend on extracellular concentrations of magnesium “as comes in [61,62,63]”.

By electron microscopy, it was found that the effects of one dose of ofloxacin can cause the same effects in cartilage of animals with a  $Mg^{2+}$ -deficient diet. The arthropathy induced by fluoroquinolones may be a tribute to the decrease of the functionally available  $Mg^{2+}$  in the cartilage of the joint “[64]”. The supplementation of  $Mg^{2+}$  accompanying with the fluoroquinolone's treatment can decrease the cartilage lesions “[65]”. In immature dogs, the  $Mg^{2+}$ -deficient diet can induce the similar clinical features as quinolones. Alterations in fibronectin staining and other extracellular structures were seen “[66]”. This explains that the addition of  $Mg^{2+}$  can restore the extracellular  $Mg^{2+}$ -dependent inter cell interactions in condylar cartilage.

Iron chelation can mediate the epigenetic changes. The dioxygenase (HIF-1 $\alpha$ ) mRNA translation inhibition, and the repression of prolyl 4-hydroxylase (P4HA1) and lysyl hydroxylase (LH1) transcription, may be result also in toxicity “as mentioned by [60,67,68]”. Fluoroquinolones is a potent iron chelator like deferoxamine, and this iron chelation resulted in suppression of collagen prolyl hydroxylation as well as DNA and histone hypermethylation “[69]”.

##### 3.4.2. Induced apoptosis

Apoptosis plays a role in fluoroquinolone induced arthropathy [70]. It was demonstrated that, after therapeutic uses of fluoroquinolones like ciprofloxacin and levofloxacin, the tissue levels of the apoptotic markers like activated caspase-3 was increased “[49]”. Apoptosis was seen even at the lowest concentration, and confirmed by electron microscopy. The condensed materials in the nucleus and apoptotic bodies can be caused after fluoroquinolones treatment “[49]”. Liu et al (2015) also found that enrofloxacin can cause increase in the malondialdehyde concentration, and induced cell apoptosis “[71]”.

### 3.4.3. Increase oxidative stress (ROS overproduction)

Many studies explained that quinolones can cause cell damage due to the induced increase the ROS. Mitochondrial DNA damage can result from the overproduction of ROS, this overproduction can trigger apoptosis by the releasing of the caspase activating markers and causing damage of tissue "[72]". Extracellular matrix components can also affect by ROS by direct cytotoxic effect, by oxidizing collagen's amino acids and by protein conformation changes, and increase in the matrix metalloproteinases, which cause a synergistical increase in the toxicity [as it was concluded by 73].

### 3.4.4. Mitochondrial damage

During quinolones treatment, the mitochondrial damage can be seen in cartilage, bone and tendon "as comes in [74,75,76]". The inhibition of the mitochondrial electron transport chain complexes activity after fluoroquinolones treatment can cause mitochondrial respiration inhibition with reduction of the ATP production "[77]". The mitochondria are important target by the oxidative stress, so the ROS overproduction can cause a severe oxidative damage to the mtDNA in cartilage cells "[78]". Cytochrome c which can be released by mitochondria causes the start of the signaling pathway and later leads to activation of caspases which causes the apoptosis and the development of tissue lesions "[79]".

### 3.4.5. Enhance the expression of matrix metalloproteinases

The matrix metalloproteinase are enzymes which play a role in response to tissue injury and in homeostasis "[72]". Studies in animals found that the fluoroquinolones can enhance the activity of matrix metalloproteinases at the mRNA in cells and affect type I collagen metabolism causing collagen degradation "as comes in [80]".

### 3.4.6. Chondrocytes loss and decrease in the formation of the cartilage extracellular matrix

It was found that fluoroquinolone treatment can significantly decrease the number of chondrocytes and the thickness of condylar cartilage with a marked decrease in collagen synthesis. The glycosaminoglycan content of the articular matrix was found to be decreased after its administration due to inhibition of DNA synthesis and inhibitory action of quinolones on proteoglycan synthesis in the chondrocytes "[81]".

## 4. Fluoroquinolone contraindications

The use of fluoroquinolones is contraindicated in patients with: Hypersensitivity "[33,82]", epilepsy or psychotic disorder, neuropathy, or with a known predisposition to seizures [83,84], tendon disorders related to fluoroquinolone administration, especially in patients with current or past treatment with oral corticosteroids "as comes in [35,85,86]", impaired renal function since they are eliminated mainly via the kidneys "[47]", and children because of the risk of musculoskeletal injury "[87]".

Because it is excreted into human breast milk and can cause arthropathy, breast-feeding should be discontinued. After two hours, the milk concentration was highest with 3.79 mg/L and it then decreased to 0.02 mg/L after one day "[88]". Fluoroquinolones must be used with caution in patients with liver diseases "[89]", cardiac diseases "[90]", myasthenia gravis "[91]", disturbances in blood glucose level "[92]", and patients treated with vitamin K antagonists "[93]".

## 5. Conclusion

Existing data from different studies consistently demonstrate that fluoroquinolone administrations are seen associated several side effects, and the fluoroquinolone chondrotoxicity is one of the important adverse effects. For this reason, fluoroquinolones are contraindicated during pregnancy, lactation period, in children and even adolescents. The possible explanation of fluoroquinolone chondrotoxicity in juvenile animals could be due to: Chelating properties against the metal ions like Mg<sup>+2</sup>, increase in the tissue levels of the apoptotic markers like activated caspase-3, oxidative stress overproduction, mitochondrial damage in condylar cartilage, enhance the enzymatic activity of matrix metalloproteinases in cells, chondrocytes loss and decrease in the formation of the cartilage extracellular matrix.

## 6. References

1. Hall M.M., Finnoff J.T., Smith J., Musculoskeletal complications of fluoroquinolones: Guidelines and precautions for usage in the athletic population. *PM and R*, 3: 132-142 (2011).
2. Stahlmann R., Clinical toxicological aspects of fluoroquinolones. *Toxicology Letters*, 127: 269-277 (2002).
3. Monique I.A., Alasdair P. M., Development of the quinolones. *J Antimicrob Chemoth*, 51 (Suppl. S1): 1-11 (2003).
4. Elbashir A.A., Dsugi N.F.A., Aboul-Enein H.Y., Supramolecular study on the interaction between ofloxacin and methyl  $\beta$ -cyclodextrin by fluorescence spectroscopy

- and its analytical application. *J Fluoresc*, 24(2):1-7(2013).
5. Blessed K., Dadah A., Yussuf M., Uba A., Quinolones resistant enteric bacteria isolated from hawked-zaki in selected parts of chicken local government area, Kaduna state Nigeria. *J Med Toxicol*, 4(1): 00085 (2008).
  6. de Almeida M.V., Saraiva M.F., de Souza M.V., da Costa C.F., et al., Synthesis and antitubercular activity of lipophilic moxifloxacin and gatifloxacin derivatives. *Bioorg Med Chem Lett*, 17(20):5661-5664(2007).
  7. Appelbaum P.C., Hunter P.A., The fluoroquinolone antibacterials: past, present and future perspectives. *International Journal of Antimicrobial Agents*, 16(1):5-11(2006).
  8. Sarkozy G., Quinolones: a class of antimicrobial agents. *Vet Med Czech*, 46:257-274 (2001).
  9. Scholar E.M., Fluoroquinolones: past, present and future of a novel group of antibacterials. *Am J Pharm Educ*, 66:164-172(2003).
  10. Sharma R.C., Jain A., Jain S., Fluoroquinolone antibacterial: A review on chemistry, microbiology, and therapeutic prospects. *Acta Poloniae Pharmaceutica Drug Research*, 66 (6):587- 604 (2009).
  11. Brar R.K., Jyoti U., Patil R.K., Patil H.C., Fluoroquinolone antibiotics: An overview. *AUJMSR*, 2(1): 26-30(2020).
  12. Fief C.A., Hoang K.G., Phipps S.D., Jessica L., et al., Examining the impact of antimicrobial fluoroquinolones on human DNA topoisomerase II $\alpha$  and II $\beta$ . *ACS Omega*, 4:4049-4055 (2019).
  13. Suh B., Lorber B., Quinolones. *Med Clin North America*, 79, 869-894(1995).
  14. Fenlon C.H., Cynamon M.H., Comparative in vitro activities of ciprofloxacin and other 4-quinolones against *Mycobacterium tuberculosis* and *Mycobacterium intracellulare*. *Antimicrob Agents Chemother*, 29: 386- 388(1986).
  15. Scroggs S.L.P., Offerdahl D.K., Flather D.P., Morris C.N, et al., Fluoroquinolone Antibiotics Exhibit Low Antiviral Activity against SARS-CoV-2 and MERS-CoV. *Viruses*, 13(8):1-12(2021).
  16. Ke W., Li D., Tso L.S., Wei R., et al., Macrolide and fluoroquinolone associated mutations in *Mycoplasma genitalium* in a retrospective study of male and female patients seeking care at a STI Clinic in Guangzhou, China, 2016-2018. *BMC Infectious Diseases*, 20(950):1-8 (2020).
  17. Zhao L., Wang S., Li X., He X., et al., Development of in vitro resistance to fluoroquinolones in *Pseudomonas aeruginosa*. *Antimicrob. Resist. Infect. Control*, 9 (124)1-8 (2020).
  18. Efthymiopoulos C., Blum B., Maroli A., Bramer S.L., Theophylline and warfarin interaction studies with grepafloxacin. *Clin Pharmacokinet*, 33:39-46 (1997).
  19. Buck M.L., Ciprofloxacin use in children: a review of recent findings. *Pediatr Pharm*, 4:12-18 (1998).
  20. Dollery C., Norfloxacin, in Therapeutic Drugs, Churchill Livingstone, p. N137-N140, Harcourt Brace and Co. Ltd., London (1998).
  21. Turnidge J., Pharmacokinetics and pharmacodynamics of fluoroquinolones. *Drugs*, 58(suppl 2):29-36 (1999).
  22. Robson R.A., Quinolone pharmacokinetics. *Intern J Antimicrob Agents*, 2:3-7 (1992).
  23. Teng R., Dogolo L.C., Willavize S.A., Friedman H.L., et al., Oral bioavailability of trovafloxacin with and without food in healthy volunteers. *J Antimicrob Chemother*, 39 Suppl B:87-92 (1997).
  24. Kepa L., Oczkogrzesik B., Stolarz W., Sobala-Szczygiel B., Drug-induced aseptic meningitis in suspected central nervous infections. *J Clin Neurosci*, 12:562-564(2005).
  25. Cheng D., Xu W.R., Liu C.X., Relationship of quantitative structure and pharmacokinetics in fluoroquinolone antibacterial. *World J Gastroenterol*, 13(17):2496-2503(2007).
  26. Von Rosenstiel N., Adam D., Quinolone antibacterial. An update of their pharmacology and therapeutic use. *Drugs*, 47: 872- 901(1994).
  27. Hamer D.H., Gorbach S.L., Use of the quinolones for the treatment and prophylaxis of bacterial gastrointestinal infections, in The Quinolones, (edit., Andriole, V.T.), Academic Press, New York NY, 1998, pp. 267-285.
  28. Gotuzzo E., Carrillo C., Mini review: Quinolones in typhoid fever. *Infect. Dis Clin Pract*, 3: 345-349 (1994).
  29. Hook E.W., Pinson G.B., Blalock C.J., Johnson R.B., Dose-ranging study of CP99, 219 (trovafloxacin) for treatment of

- uncomplicated gonorrhoea. *Antimicrob. Agents Chemother*, 40: 1720-172 (1996).
30. Saavedra S., Rivera-Vazquez C.R, Ramirez-Ronda C.H., Quinolones and sexually transmitted diseases," in The New Generation of Quinolones, (edit., Sipporin, C., Heifetz, C. and Domagala, J.), Marcel Dekker, New York NY, 1990. pp. 277-287.
  31. Yu V.L., Vergis E., New macrolides or new quinolones as monotherapy for patients with community acquired pneumonia. *Chest*, 113: 1158-1159 (1998).
  32. Alangaden G.J., Lerner S.A., The clinical use of fluoroquinolones for the treatment of mycobacterial diseases. *Clin Infect Dis*, 25: 1213-1221(1997).
  33. McGee E.U., Samuel E., Boronea N., Milby M.N., et al., Quinolone allergy. *Pharmacy*, 7:1-12(2019).
  34. Baik S., Lau J., Huser V., McDonald C.J., Association between tendon ruptures and use of fluoroquinolone, and other oral antibiotics: a 10-year retrospective study of 1 million US senior Medicare beneficiaries. *BMJ Open*, 10:1-14(2020).
  35. Alkaissi H., Kolla S., Page C., Salam L., et al., Fluoroquinolone-induced rotator cuff tendinopathy: A case report. *Am J Med Case Rep*, 9(2): 122–124.(2021).
  36. Ross R., Kinlaw A.C., Herzog M.M., Funk M.J., et al., Fluoroquinolone antibiotics and tendon injury in adolescents. *Pediatrics*, 147(6): e2020033316(2021).
  37. Huruba M., Farcas A., Leucuta D.C., Bucsa C., et al., A VigiBase descriptive study of fluoroquinolone induced disabling and potentially permanent musculoskeletal and connective tissue disorders. *Scientific Reports*, 11:14375 (2021).
  38. Lewis T., Cook J., Fluoroquinolones and tendinopathy: a guide for athletes and sports clinicians and a systematic review of the literature. *Journal of Athletic Training*, 49 (3): 422–427(2014).
  39. Moorthy N., Raghavendra N., Venkatarathnam P.N., Levofloxacin-induced acute psychosis. *Indian Journal of Psychiatry*, 50(1):57-58(2008).
  40. Francis K., Higgins E., Permanent peripheral neuropathy: a case report on a rare but serious debilitating side-effect of fluoroquinolone administration. *J. Investig. Med. High Impact Case Rep*, 2(3):1-6 (2014).
  41. Korhale D.V, Khandewale V.A, Deshmukh S.B, Ashish V., et al., Incidence of fluoroquinolone induce psychotic disorders in patients admitted to department of medicine in a general hospital setup. *J of Evolution of Med and Dent Sci*, 4: 14942-14948 (2015).
  42. Owens R.C, Ambrose P.G., Antimicrobial safety: focus on fluoroquinolones. *ClinInfectDis*, 41(2):S144–157 (2005).
  43. Strange J.E., Holt A., Blanche P., Gislason G., et al., Oral fluoroquinolones and risk of aortic or mitral regurgitation: a nationwide nested case-control study. *European Heart Journal*, 42(30): 2899–2908 (2021).
  44. Coban S., Ceydilek B., Ekiz F., Erden E., et al., Levofloxacin-induced acute fulminant hepatic failure in a patient with chronic hepatitis B infection. *Ann Pharmacother*, 39 (10): 1737–1740 (2005).
  45. Hsiao C.J, Younis H., Boelsterli U.A., Trovafloxacin, a fluoroquinolone antibiotic with hepatotoxic potential, causes mitochondrial peroxynitrite stress in a mouse model of underlying mitochondrial dysfunction. *Chemico-Biological Interactions*, 188(1): 204–213(2010).
  46. Telfer S.J., Fluoroquinolone antibiotics and type 2 diabetes mellitus. *Medical Hypotheses*, 83(3): 263–269 (2014).
  47. Matsubara R., Kibe R., Nomura T., Crystalline nephropathy caused by tosufloxacin. *Pediatrics International*, 58(11): 1219–1221(2016).
  48. Vaughn V.M., Seelye S.M., Wang X.Q, Wiitala W.L., et al., Inpatient and discharge fluoroquinolone prescribing inveterans' affairs hospitals between 2014 and 2017. *Ofid*, 13:1-8(2020).
  49. Sendzik J., Shakibaei M., Schafer-Korting M., Stahlmann R., Fluoroquinolones cause changes in extracellular matrix, signaling proteins, metalloproteinases and caspase-3 in cultured human tendon cells. *Toxicology*, 212(1):24-36 (2005).
  50. Lozo E., Riecke K., Schwabe R., Vormann J., et al., Synergistic effect of ofloxacin and magnesium deficiency on joint cartilage in immature rats. *Antimicrob. Agents Chemother*, 46(6): 1755-1759 (2002).
  51. Christ W., Lehnert T., Ulbrich B., Specific toxicological aspects of the quinolones. *RevInfect Dis*, 10(1):S141-S146 (1988).
  52. Christ W., Lehnert T., Toxicity of the quinolones. In: The new generation of quinolones, CSiporin, CL Heifetz, and JM Domagala (eds). Marcel Dekker, New York, 1990, pp 165-186.
  53. Gough A.W., Barsoum N.J., Renlund R.C., Sturgess J.M., et al., Fine

- structural changes during reparative phase of canine drug induced arthropathy. *Vet Pathol*, 22:82-84(1985).
54. Gough A.W., Johnson R., Campbell E., Hall L., et al., Quinolone arthropathy in immature rabbits treated with the fluoroquinolones. *Exp Toxicol Pathol*, 48: 225-232 (1996).
  55. Kato M., Onodera T., Morphological investigation of cavity formation in articular cartilage induced by ofloxacin in rats. *Fundam Appl Toxicol*, 11: 110-119 (1988).
  56. Bendele A.M., Hulman J.F., Harvey A.K., Hrubey P.D., et al., Passive role of articular chondrocytes in quinolone-induced arthropathy in guinea pigs. *Toxicol Pathol*, 18(2): 304-312(1990).
  57. Davenport C.L.M., Boston R.C., Richardson D.W., Effects of enrofloxacin and magnesium deficiency on matrix metabolism in equine articular cartilage. *Am J Vet Res*, 62: 160-166 (2001).
  58. Kato M., Chondrotoxicity of Quinolone Antimicrobial Agent. *J Toxicol Pathol*, 21:123-131 (2008).
  59. Uivarosi V., Metal complexes of quinolone antibiotics and their applications: an update. *Molecules*, 18(9): 11153-11197(2013).
  60. Khaliq Y., Zhane G., Musculoskeletal Injury Associated with Fluoroquinolone Antibiotics. *Clinics in Plastic Surgery*, 32(4): 495-502(2005).
  61. Kairchhofer D., Grzesiak J., Pierschbacher M.D., Calcium as a potential physiological regulator of integrin-mediated cell adhesion. *J Biol Chem*, 266:4471-4477(1991).
  62. Enomoto M.P., Leboy S., Menko A.S., Boettiger D., B1 integrins mediate chondrocyte interaction with type I collagen, type II collagen, and fibronectin. *Exp Cell Res*, 205:276-285 (1993).
  63. Stahlmann R., Förster C., Shakibaei M., Decrease of Beta1-integrins in cartilage from juvenile rats after ofloxacin treatment. *Naunyn-Schmiedebergs Arch Pharmacol*, 348:170-176 (1993).
  64. Shakibaei M., Kociok K., Förster C., Vormann J., et al., Comparative evaluation of ultrastructural changes in articular cartilage of ofloxacin-treated and magnesium-deficient immature rats. *Toxicologic Pathology*, 24 (5):580-587 (1996).
  65. Egerbacher M., Wolfesberger B., Gabler C., In vitro evidence for effects of magnesium supplementation on quinolone-treated horse and dog chondrocytes. *Veterinary Pathology*, 38(2): 143-148 (2001).
  66. Stahlmann R., Kuhner S., Shakibaei M., Flores J., et al., Effects of magnesium deficiency on joint cartilage in immature beagle dogs: immunohistochemistry, electron microscopy, and mineral concentrations. *Arch Toxicol*, 73: 573-580 (2000).
  67. Stahlmann R., Forster C., Shakibaei M., Vormann J., et al., Magnesium deficiency induces joint cartilage lesions in juvenile rats which are identical to quinolone-induced arthropathy. *Antimicrob Agents Chemother*, 39: 2013-2018(1995).
  68. Goldie F.C., Brogan A., Boyle J.G. Ciprofloxacin and statin interaction: a cautionary tale of rhabdomyolysis. *BMJ Case Reports*, 13:1-2(2016).
  69. Badal S., Her Y.F., Maher L.J., Nonantibiotic effects of fluoroquinolones in mammalian. *Cells J Biol Chem*, 4(36):22287-22297(2015).
  70. Khazaeel K., Mazaheri Y., Tabar M.H., Najafzadeh H., et al., Effect of enrofloxacin on histochemistry, immunohistochemistry and molecular changes in lamb articular cartilage. *Acta Medical Iranica*, 53(9): 555-561(2015).
  71. Liu B., Cui Y., Brown P.B., Ge X., et al., Cytotoxic effects and apoptosis induction of enrofloxacin in hepatic cell line of grass carp (*Ctenopharyngodon idellus*). *Fish and Shellfish Immunology*, 47(2): 639-644(2015).
  72. Pouzaud F., Bernard-Beaubois K., Thevenin M., Warnet J.M., et al., In vitro discrimination of fluoroquinolones toxicity on tendon cells: Involvement of oxidative stress. *J Pharmacol Exp Ther*, 308(1): 394-402(2004).
  73. Maślanka T., Jaroszewski J.J., Mikołajczyk A., Rotkiewicz T., Effect of increasing doses of enrofloxacin on chicken articular cartilage. *Polish Journal of Veterinary Sciences*, 12 (1): 21-33 (2009).
  74. Lowes D.A., Wallace C., Murphy M.P., Webster N.R., et al., The mitochondria targeted antioxidant MitoQ protects against fluoroquinolone-induced oxidative stress and mitochondrial membrane damage in human Achilles tendon cells. *Free Radical Research*, 43(4): 323-328(2009).
  75. Barnhill A.E., Brewer M.T., Carlson S.A., Adverse effects of antimicrobials via predictable or idiosyncratic inhibition of



- host mitochondrial components. *Antimicrobial Agents and Chemotherapy*, 56(8): 4046–4051(2012).
76. Stahlmann R., Lode H.M., Risks associated with the therapeutic use of fluoroquinolones. *Expert Opinion on Drug Safety*, 12(4): 497–505(2013).
77. Song M., Wu H., Wu S., Ge T., et al., Antibiotic drug levofloxacin inhibits proliferation and induces apoptosis of lung cancer cells through inducing mitochondrial dysfunction and oxidative damage. *Biomedicine and Pharmacotherapy*, 84: 1137–1143(2016).
78. Kalghatgi S., Spina C.S., Costello J.C., Liesa M., et al., Bactericidal antibiotics induce mitochondrial dysfunction and oxidative damage in mammalian cells. *Science Translational Medicine*, 5(192):192ra85(2013).
79. Kalegasioglu F., Olcay E., Fluoroquinolone-induced tendinopathy: etiology and preventive measures. *Tohoku J Exp Med*, 226(4): 251–258 (2012).
80. Tsai W.C., Hsu C.C., Chen C.P.C., Chang H.N., et al., Ciprofloxacin up-regulates tendon cells to express matrix metalloproteinase-2 with degradation of type I collagen. *J Orthop Res*, 29(1): 67–73(2011).
81. Halawa A.M., Effects of ciprofloxacin on the articular cartilage and epiphyseal growth plate cartilage in the growing albino rats and the possible protective role of vitamin E (alpha-Tocopherole): A histological and morphometric study. *Egyptian Journal of Histology*, 33(3):1-5(2010).
82. Eluri P., Vipparla K., Suryadevara V., Ofloxacin induced hypersensitivity reaction. *Int J Res Med Sci*, 3(1):349-351(2015).
83. Kaur K., Fayad R., Saxena A., Bennett C., Fluoroquinolone-related neuropsychiatric and mitochondrial toxicity: a collaborative investigation by scientists and members of a social network. *JCSO*, 14(2)54–65(2016).
84. Ghavanini A.A., Do Fluoroquinolones Cause Neuropathy? *Neurol Neurosurg*, 3(1):1-3(2017).
85. Sode J., Obel N., Hallas J., Lassen A., Use of fluoroquinolone and risk of Achilles tendon rupture: a population-based cohort study. *Eur J Clin Pharmacol*, 63 (5): 499-506 (2007).
86. Baombe JP., Ford R. Do fluoroquinolones increase the incidence of tendinopathy? *Emerg Med J*, 33(7): 519–522 (2016).
87. Polachek H., Leibovitz E., Dagan R., Joint cartilage lesions caused by quinolones in young animals--can we generalize to children? *Harefuah*, 150 (9):721-724(2011).
88. Bar-Oz B., Bulkowstein M., Benyamini L., Berkovitch M., Use of antibiotic and analgesic drugs during lactation. *Drug Safety*, 26(13):925-935(2003).
89. Shaw P.J., Ganey P.E., Roth R.A., Idiosyncratic drug-induced liver injury and the role of inflammatory stress with an emphasis on an animal model of trovafloxacin hepatotoxicity. *Toxicol Sci*, 118(1):7-18 (2010).
90. Rubinstein E., Camm J., Cardiotoxicity of fluoroquinolones. *J Antimicrob Chemother*, 49 (4): 593–596(2002).
91. Jones S.C., Sorbello A., Boucher R.M., Fluoroquinolone-associated myasthenia gravis exacerbation: evaluation of postmarketing reports from the US FDA adverse event reporting system and a literature review. *Drug Saf*, 34(10):839-847 (2011).
92. Shehab N., Patel P.R., Srinivasan A., Budnitz D.S., Emergency department visits for antibiotic-associated adverse events. *Clin Infect Dis*, 47 (6): 735–743 (2008).
93. Jolson H.M., Tanner L.A., Green L., Grasela T.H., Adverse reaction reporting of interaction between warfarin and fluoroquinolones. *Archives of Internal Medicine*, 151: 1003–1004(1991).

#### النواحي السمية لاستخدام الفلوروكينولون مراجعه مقالات

اميره كمال خليل<sup>1</sup>، راميزو بن شاري<sup>2</sup>، محمد عريف اوانك ناوي<sup>3</sup>، على محسن حسين الياسري<sup>4</sup>

المجمع الجامعي الصحي، جامعة ساينس ماليزيا، كوبانج 3، 1,2، كيريان، 16150 كوتا بارو، كيلانتان، ماليزيا  
رئيس قسم طب الأسنان، كلية الحلة الجامعه، بابل العراق 4

#### الخلاصه

تظهر السمية المرتبطة بالفلوروكينولون بعد العلاج طويل الأمد بالمضادات الحيوية بالفلوروكينولون كمشكلة طبية واجتماعية كبيرة. كان الهدف من هذه المراجعة بشكل أساسي هو تحديد وجمع وتقييم البنية المتاحة فيما يتعلق بالجوانب السمية للفلوروكينولون مع التركيز على أسباب السمية الغضروفية بالفلوروكينولون في الحيوانات البيافعة. أجريت المراجعة الحالية باستخدام قواعد بيانات PubMed / Medline. تم تضمين المنشورات باللغة الإنجليزية والدراسات الأصلية والمراجعات. تمت مراجعة جميع الأعمال المتعلقة بالفلوروكينولونات المتعلقة بالدراسات البشرية والمختبرية والحيوانية المنشورة في الأدبيات الطبية وطب الأسنان بين عامي 1985 و 2021. تظهر دراسات البيانات الحالية أن إعطاء الفلوروكينولون يمكن أن يسبب آثارًا جانبية مختلفة، والسمية الغضروفية الفلوروكينولون في الحيوانات الصغيرة هي واحدة منها. قد يكون السبب هو ارتباط الفلوروكينولون بالكاتيونات ثنائية التكافؤ مثل Mg+2 ويمكن أن يؤدي ذلك إلى نقص المغنيسيوم المتاح وظيفيًا، وزيادة مستوى علامات موت الخلايا المبرمج في الأنسجة مثل كاسباس المنشط - 3، والإفراط في إنتاج أنواع الأكسجين التفاعلية (ROS)، وتلف المايوتوكندريا، وعزز التعبير عن الماتريكس ميتالوبوتينيسيس. اعتمادًا على هذه النتائج السمية في الدراسات التي أجريت على الحيوانات أثناء النمو بعد الولادة، يتم منع استخدام الفلوروكينولونات أثناء الحمل والرضاعة وعند الأطفال